

Research Article

Comparison of efficacy of Oral versus Intra-articular Corticosteroid Application in the treatment of Frozen Shoulder: An experimental study in rats

Bekir Murat Çınar¹ , Vahit Erdal Battal¹ , Nebil Bal² , Ümit Özgür Güler¹ , Salih Beyaz¹ ¹Department of Orthopaedics and Traumatology, Başkent University, Adana Training and Research Center, Adana, Turkey²Department of Pathology, Başkent University, Adana Training and Research Center, Adana, Turkey

ARTICLE INFO

Article history:

Submitted September 14, 2020

Received in revised form

October 4, 2021

Last revision received

November 23, 2021

Accepted December 2, 2021

Keywords:

Frozen shoulder

Adhesive capsulitis

Corticosteroid

Animal model

ORCID iDs of the authors:

B.M.Ç. 0000-0002-7906-5039;

V.E.B. 0000-0003-0044-2899;

N.B. 0000-0003-3154-2606;

Ü.Ö.G. 0000-0002-5375-635X;

S.B. 0000-0002-5788-5116.

ABSTRACT

Objective: The aim of this study was to compare clinical and histopathological effects of oral versus intraarticular corticosteroid application in a rat model of frozen shoulder.**Methods:** In this study, eighty adult Sprague-Dawley rats were used. The animals were divided into 5 equal groups. The frozen shoulder model was created by immobilizing animals' shoulders with internal fixation with sutures for 8 weeks. At the 8th week, sham (n: 16) and control (n: 16) groups were sacrificed to collect data for healthy and affected shoulders. Also, at the 8th week, 50 mg/kg methylprednisolone was started for the oral treatment group, and a single dose of 0.5 mg/kg triamcinolone acetonide was injected for the intraarticular treatment group. The effect of additional steroid treatment was expected for 2 weeks, then all remaining treatment and natural course groups were sacrificed on the 10th week.**Results:** After sacrifice, specimens taken as "en bloc" scapulothoracic disarticulation were randomly divided into two groups for a range of motion measurement and histopathological examination. The control (frozen shoulder model) group's shoulder range of motion in all directions was lower than the sham (healthy) group ($P < 0.01$). Natural course and intraarticular steroid groups, compared to the frozen shoulder model showed a significant increase in the direction of abduction ($P < 0.05$). Also, it was found for treatment groups that in all directions the range of motion was not as good as the healthy values ($P < 0.01$). The intraarticular treatment group showed higher degrees of abduction compared to the natural course and oral steroid treatment groups ($P < 0.01$). Oral steroid treatment group's range of motion was not significantly better than the disease model and had no superiority to the natural course group ($P > 0.05$). Histopathologically, no statistically significant difference was observed between the groups for signs of frozen shoulder which was found in the immobilized group ($P > 0.05$). Histopathologically, immobilization was found to cause thickening of the capsule that cannot be resolved by treatment. ($P < 0.05$).**Conclusion:** In frozen shoulder disease, intraarticular steroid injection seems to be superior in increasing the range of motion than oral steroid treatment.

Introduction

Adhesive capsulitis disease is a very unique condition, as the shoulder is the only joint in the body affected by this condition. Initially, patients usually complain of shoulder pain that occurs only at night. Subsequently, joint inflammation and capsule thickening lead to severe pain, limited shoulder activity, and daily restrictions. Clinically, frozen shoulder can be divided into freezing, frozen, and thawing stages and each phase of disease lasts about 6 months.¹⁻³ Fibrinous synovial inflammation of the capsule is one of the hallmarks of the frozen shoulder. In the literature, there are few clinical studies on this subject.^{4,5} Also, the experimental animal model of frozen shoulder has been previously reported in the literature.⁶⁻¹⁰

Treatment of the frozen shoulder is mainly conservative, including the introduction of analgesic drug and physiotherapy. Reducing pain and inflammation allows the conditions process to be resolved in less time. Intraarticular (IA) steroid injection and oral ster-

oid administration have been frequently used for this purpose.¹¹⁻¹⁴ Pain and joint adhesion are thought to be reduced as a result of the decrease in the inflammation process due to the effect of the steroid. To the best of our knowledge, few clinical studies have investigated the use of cortisone in the literature and all have shown positive short-term results. Recently, oral cortisone administration in this disease has become a promising strategy.^{15,16} Despite clinical studies focusing on this issue, there is still controversy over whether the most appropriate treatment for frozen shoulder is IA steroid injection or oral steroids. However, there are no studies comparing the effectiveness of different use of cortisone in this disease in the in vitro setting. In the present study, we hypothesized that the success rates of cortisone application in frozen shoulder would not be similar using different methods. We, for the first time in the literature, aimed to compare the effect of oral and IA corticosteroid treatments on clinical and histopathological findings in the treatment of frozen shoulder in an experimental model.

Corresponding Author:

Bekir Murat Çınar
cinarm@gmail.com

Content of this journal is licensed under a Creative Commons Attribution-NonCommercial 4.0 International License.

Cite this article as: Çınar BM, Battal VE, Bal N, Güler ÜÖ, Beyaz S. Comparison of efficacy of Oral versus Intra-articular Corticosteroid Application in the treatment of Frozen Shoulder: An experimental study in rats. Acta Orthop Traumatol Turc 2022; 56(1):64-70.

Materials and Methods

This study was approved by the institutional Medical and Health Sciences Research Committee and the Animal Experiments Ethical Committee (Protocol no. DA 16/12; Dated: 22/02/2016). A total of 80, eight-month-old female Sprague–Dawley rats (250-300 g) were randomly divided into one sham and four immobilization groups (n = 16 in each group). In the immobilization groups, left glenohumeral joint of each animal was immobilized with a procedure described by Villa-Camacho et al.¹⁰ for 8 weeks.

The surgical procedures were performed under general anesthesia with an intraperitoneal injection of 50 mg/kg of ketamine (Brema®, Germany) and 7 mg/kg of xylazine (Alfazyne®, Netherlands). A skin incision (~15 mm) was made in the beginning on the inferior edge of the scapula and aiming toward humeral shaft. After the scapula was exposed between latissimus dorsi and trapezius muscles, two small holes were made in the inferior angle of the scapula using a 23-gauge needle. Distal part of the humeral shaft was exposed between triceps and brachialis muscles while protecting the radial nerve. Two braided polyester sutures (no. 2-0, TI-CRON) were passed from the holes on the scapula and tied with the humeral shaft to immobilize the glenohumeral joint. In the sham group, the same surgical procedure was applied, but sutures were only tied to scapula, allowing the shoulder joint free motion. To avoid secondary trauma, minimal muscle dissection was made and soft tissue was not manipulated during the procedure. The animals were allowed normal cage activity immediately after the procedure. They were able to walk and feed themselves and no rehabilitation or activity restraints were applied. A total of 10 mg/kg enrofloxacin (Baytril-K®, Germany) was given subcutaneously as an antibiotic for 3 days. The rats were allowed for free cage activity in Week 8.

After 8 weeks of immobilization, under general anesthesia, from the same incision, the sutures were removed. Glenohumeral joint mobility was confirmed after the procedure, but no forced manipulation was applied. Sham group was sacrificed to obtain data of healthy shoulder and control group was sacrificed to evaluate the effect of immobilization. The remaining was divided into the natural course group without medication, the group receiving IA cortisone, and the group receiving oral cortisone. The effect of treatment was observed in free cage activity for two more weeks. All postoperative procedures performed after the first operation were repeated in this process. The remaining groups were sacrificed at Week 10 by intraperitoneal injection of ketamine (150 mg/kg euthanasia dose). After sacrifice, each group was randomly divided into two groups to evaluate changes in range of motion (ROM) and for histopathological investigation.

Kanno et al.⁶ reported that the pathology was caused by the capsule due to the fact that there was no significant difference in abduction values between the existence and stripping of muscles in the immobilized group and a significant increase after capsulotomy. Therefore, in our study, we performed measurements after *en-bloc* resection

without any muscle dissection before the procedure. In particular, the measurement without freezing of resection materials reduces the possibility of possible extra-articular adhesion.

Drug Application

IA steroid

A single IA injection was made during second operation at Week 8. Under general anesthesia, after the sutures were removed, the shoulder joint was determined from the same incision. After the capsular tissue was passed, the needle tip was placed between the humerus and the glenoid. Then, 0.2 mL, 0.5 mg/kg triamcinolone acetonide (Kenakort®, USA) was administered to the joint space and the capsule was observed to swell. In our previous pilot study, we observed that the injection technique was successful and did not cause hydrodilution in the capsule by injecting 0.2 mL of methylene blue intraarticularly with the posterior approach.

Oral steroid

Oral steroid treatment was started with 50 mg/kg methylprednisolone (Prednol®, Turkey) 24 h after the second operation at Week 8.¹⁷ Tablets were reconstituted in 16 cc sf by calculating the total dose of 16 rats and each was given as 1 cc gavage to each rats. Drug doses were given in accordance with diurnal rhythm after 30 min of hunger and thirst in the morning. To prevent adrenal insufficiency, the drug dose was reduced to half in every 2 days and was terminated in eight days.

Evaluation of Glenohumeral ROM

After sacrifice, the left upper extremity was removed in an *en-bloc* fashion by scapulothoracic disarticulation and the skin was ripped off. First, the internal rotation, then the external rotation, and finally the abduction degrees were measured. The measurements were performed once for each direction to avoid tissue stiffness and photographed by standards within 5 min of tissue collection. Angle measurements were performed using a special smart phone measurement program (Partometer 3D – vistech.projects) which corrects angular deformity caused by photograph plane (Figure 1). All measurements were made by applying a standard force of 0.098 N (using a 10-g weight). To keep the torque applied on shoulder constant, the weight attached on a string was hanged vertically on the same distance (~20 mm) to the center of rotation

To measure internal rotation, the specimen was pinned from scapula (thoracic side facing downward) on top side of a Styrofoam, thereby restricting the motion of the glenohumeral joint roughly to the internal and external rotational plane. Hand and lower arm were located hanging on side of the Styrofoam and elbow was placed at the corner of Styrofoam. At this position, 10-g weight on a string was hung on the wrists of the animals and Styrofoam was manually rotated to achieve 90° between ulna and string (ulna was parallel to ground). The internal rotation ROM, which was defined as the angle between scapular plane and ulna, was measured on photographs and recorded.

To measure external rotation, scapula was turned on its back and pinned dorsal side facing downward on top side of the Styrofoam. The position of elbow and lower arm was similar to previous measurement, and the same standard torque was applied. In this position, the ulna was parallel to ground photograph and was taken to measure the angle between scapular plane and ulna.

Abduction measurement was made as previously described by Oki et al.¹³ Briefly, the humerus was amputated at its distal 1/3 and a 27-gauge needle was inserted into humeral shaft from distal to proximal.

HIGHLIGHTS

- With the method we used in this study, we have created a successful frozen shoulder model.
- In frozen shoulder, more joint movement is achieved with the intraarticular application of cortisone therapy.
- Despite the administration of cortisol during the histopathological recovery of frozen shoulder, complete recovery could not be achieved.



Figure 1. a, b. Rotation measurements on sacrificial rat shoulders made with the Partometer3d-vistech.projects program. In Figure a, the yellow A line was drawn on the ulna shaft while the blue B line was placed parallel to the scapula, and the angle between two lines was measured as internal rotation. On the other hand, in Figure b, while the yellow A line was drawn parallel to the scapula, the blue B line was drawn on the ulna shaft, and the angle between the two lines was measured as external rotation.

Scapula was pinned on the front side of Styrofoam (thoracic side facing to Styrofoam), allowing the humerus motion only on abduction and adduction plane. The same 10-g weight was attached to the distal end of the needle (~20 mm). The specimen attached to Styrofoam block was turned on the abduction plane, until humeral shaft was parallel to ground and photographed. Abduction ROM was defined as the angle between spina scapula and humeral shaft.

Histological assessments

For histopathological examination, the left upper extremity skin was dissected and removed. The samples were stored in 10% formaldehyde solution in a 100 mL volume lid container, separately for each subject without compression, in the natural abduction position.

Coronal section of the shoulder joints (parallel to the scapula) was performed and the tissue samples were subjected to fixation and follow-up after decalcification of 24-48 h in 10% formic acid. Five-micron sections were taken into the slides from the tissues embedded in paraffin blocks.

Samples for routine histopathology evaluation were stained with hematoxylin-eosin (H&E) routine stain. The stained specimens were evaluated under light microscope (Olympus BX51, USA) for inflammation, capillary proliferation, fibroblast proliferation, collagen deposition density, synovial surface structure in the recessus axillaris and capsular thickness parameters (Figure 2). Evaluation of the stained preparations under light microscope was done as follows: 1. Inflammation; no, yes- mild, yes- severe; 2. Capillary proliferation; Capillary vessel count was counted and averaged in 2 BBA (large magnification = X 400); 3. Fibroblast proliferation; absent (less than

20 fibroblastic cells in a BBA), mild (presence of 20-50 fibroblastic cells in a BBA), severe (more than 50 fibroblastic cells in a BBA); 4. Collagen density was evaluated as absent, mild accumulation, and severe accumulation; 5. Axillary pouch (recessus axillaris); synovial intima having many folds, few folds, flat; and 6. Shoulder joint capsule thickness; the digital image taken at X 100 magnification was evaluated using the Image-J program in the computer environment. The thickness of the capsule was measured from the three thickest points in the axillary pouch, the perpendicular distance to the joint as pixel value, and the average value was taken.

Statistical analysis

Statistical analysis was performed using the SPSS version 17.0 software (SPSS Inc., Chicago, IL, USA). Continuous data were expressed in median (min-max), while categorical data were expressed in number and percentage. In the comparison of continuous measurements between the groups, the distributions were checked, and the Kruskal-Wallis test and Mann-Whitney *U*-test were used, since the prerequisite of parametric distribution was not met. The chi-square test or Fisher exact test was used to compare categorical variables. A $P < 0.05$ was considered statistically significant.

Results

Two rats were excluded from the study from the experimental group given oral cortisone, due to the development of an infection in a rat from the subgroup in which ROM was measured and a rat died from the subgroup, in which histological evaluation was performed. No adverse conditions were observed in remaining rats in the experimental stage.

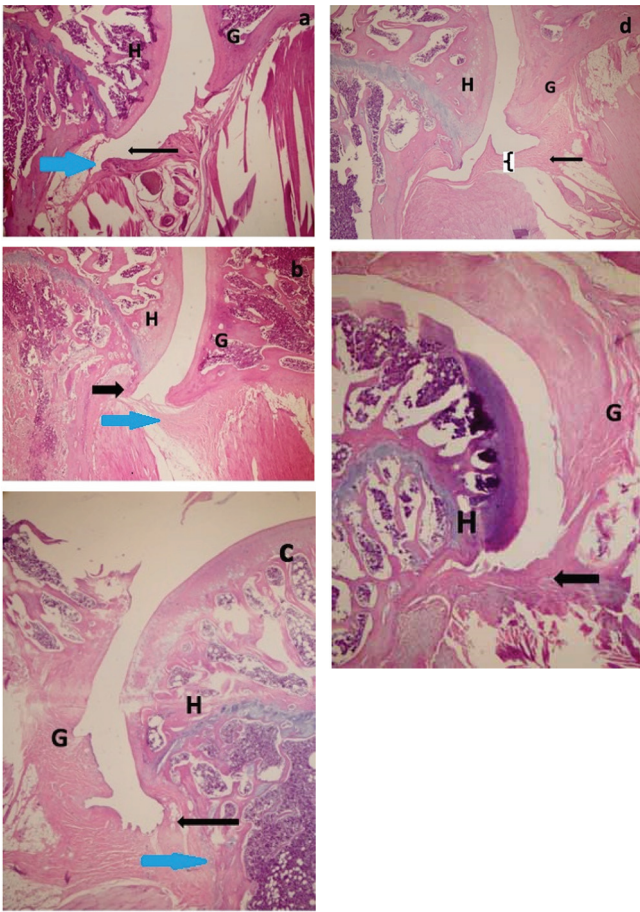


Figure 2. a-e. Histological analysis of the glenohumeral joint. (40x view of hematoxylin and eosin (H&E) stained section) (a) shoulder in sham group. The blue arrow indicates the axillary pouch fold structure and the black arrow indicates the width of the axillary pouch. (b) Shoulder in control group. The blue arrow indicates fibroblast proliferation and collagen deposition, and the black arrow indicates narrowing of the axillary pouch. (c) Shoulder in natural course. The blue arrow indicates capillary proliferation and the black arrow indicates axillary pouch. (d) Shoulder in intraarticular cortisone. Curly bruckert shows capsular thickness. (e) Shoulder in oral cortisone. In the axillary pouch (arrow), the curved capsular surface structure and capsule thickness in the sham group have been shown to increase and flatten in other groups. There was no difference in capsule thickness, collagen density, and capillary growth in other groups except for the sham group. H stands for Humeral Head; G stands for Glenoid.

ROM Group

The degree of shoulder joint ROM of the control (disease model) group in all directions was significantly lower compared to the sham (healthy) group (internal rotation $P = 0.007$, external rotation $P = 0.005$, abduction $P = 0.001$, and total rotation $P = 0.000$). Therefore, it was confirmed that the frozen shoulder model was successfully created. The rats followed in its natural course improved compared to the disease model in terms of abduction; however, the degrees of rotation did not improve sufficiently. Compared to the sham group (healthy) of the natural course group, the ROM of the shoulder joint in all directions was significantly lower (internal rotation $P = 0.007$, external rotation $P = 0.003$, abduction $P = 0.000$, and total rotation $P = 0.001$). Therefore, two weeks after the shoulder release (Week 10), the disease did not fully recover in its natural course in rats and that it was at a level that would make a difference with the healthy group. Compared to the control group (disease) of the IA steroid group, only a significant increase in abduction angle was detected ($P = 0.001$). Compared to the sham group (healthy),

the shoulder joint ROM of the IA steroid group was significantly lower in all directions (Table 1). Despite IA steroid therapy, the degree of ROM of the shoulder joints was not as good as that of the healthy group. Compared to the natural course, the difference in the abduction value that was higher in the IA steroid group was found to be significant ($P = 0.001$). In the IA steroid group, in other directions, the findings were better than the natural course, but were not statistically significant (internal rotation $P = 0.959$, external rotation $P = 0.130$, and total rotation $P = 0.161$).

The increase in joint ROM of the oral steroid group was not significant in any direction compared to the control and sham groups. On the other hand, although the angle of rotation was more than the natural group, no significant improvement was observed. When IA and oral steroid treatment was compared, no statistically significant difference was found in terms of rotational values (internal rotation $P = 1.000$, external rotation $P = 0.955$, and total rotation $P = 0.463$). The abduction levels of the highest IA injection group after the sham group were found to be significantly superior to the oral steroid group ($P = 0.001$).

Histological Investigation

In the light microscope, mild inflammation was detected in the H&E-stained specimens only in two rats, one rat in the natural course group and one rat in the IA steroid group. Inflammation did not show a statistically significant difference with the other groups ($P = 0.574$) and there was no significant difference in the evaluation of other parameters of the rats with inflammation. Therefore, the rats with mild inflammation were not excluded from the study. No signs of severe inflammation were observed in any of the subjects (Table 2).

As decreased capillary proliferation is an expected condition in frozen shoulder disease, the capillary number of the lowest oral steroid groups was significantly lower than the sham group ($P = 0.013$), suggesting that oral steroid treatment did not increase the number of capillaries decreased in frozen shoulder disease. There was no significant difference in capillary proliferation compared to other groups ($P > 0.05$).

In terms of fibroblast proliferation, fibroblast increase was not detected in one rat each in the control group and in the natural course group, whereas a slight increase was detected in seven rats each. In the sham group, fibroblastic cell increase was not detected in six rats, while mild fibroblastic proliferation was found in two rats. Although it was less common in the treatment groups than in the control and natural course groups, fibroblastic proliferation was observed, but it did not reach statistical significance ($P = 0.077$). The presence of severe fibroblastic cell increase in one rat each in the IA and oral steroid groups indicated that corticosteroids increased fibroblastic proliferation.

Collagen density was measured in a similar distribution in all groups and there was no statistically significant difference between the groups in terms of collagen density in H&E-stained preparations ($P = 0.342$).

In the sham group, more than half of the natural course and IA steroid groups had a very curved capsule surface, but more than half of the control and oral steroid groups were observed to be lost on the very curved surface (Figure 2). Although the success of the oral steroid group was low, it was not statistically significant ($P = 0.206$).

Table 1. Range of motion data of the groups

		Mean	Median	Minimum	Maximum	Number of subject
Control	IR	27.64	25.79	15.40	42.01	8
	ER	24.17	26.16	10.46	33.77	8
	ABD	89.59	93.68	61.81	102.07	7
Sham	IR	40.10	40.28	34.64	46.40	8
	ER	39.98	37.15	29.40	53.48	8
	ABD	174.67	178.77	142.19	191.27	7
Natural course	IR	27.95	29.42	12.89	42.70	8
	ER	21.14	22.66	8.94	33.40	8
	ABD	116.09	122.85	93.75	137.49	7
Intraarticular cortisone	IR	29.39	29.74	20.50	35.29	8
	ER	28.71	28.73	20.22	35.27	8
	ABD	148.03	146.77	138.16	165.89	8
Oral cortisone	IR	34.24	27.67	23.00	56.13	7
	ER	30.01	29.60	18.51	45.19	7
	ABD	107.99	104.19	87.01	129.45	7

Although there was a significant difference between the shoulder joint capsule thickness in the sham group and other groups, no difference was found between the other groups. The capsule which thickened on the frozen shoulder did not recover in a short time, despite steroid treatment. The presence of immunohistochemical type III collagen was evaluated according to the intensity of staining under the light microscope; however, there was no statistically significant difference between the groups ($P = 0.932$).

Discussion

In the present study, we demonstrated that frozen shoulder disease can be created with the experimental model in rats and, as the main finding of this study, we found that IA corticosteroid injection

increased rat shoulder motion better than oral corticosteroid administration. Since the pathogenesis and response to treatment of frozen shoulder disease is not fully known, it is useful to work in an animal model. It is not possible to create primary frozen shoulder disease in an animal model. Therefore, it is preferable to create a secondary frozen shoulder disease with the joint immobilization model.⁶⁻¹⁰ Animal experiments on the frozen shoulder were first performed by Schollmeier et al.^{18,19} by cast immobilization of canine shoulder. They claimed that, with the end of immobilization, the pathology improved and the model was similar to frozen shoulder disease. The shoulder immobilization model using suture material was first described by Ochiai et al.⁸ Similarly, in our study, the humerus and scapula of the rat were tied with a double suture to an established experimental model. The general knowledge for the pathological process in frozen shoulder disease is that it begins with synovial inflammation and results in fibrosis in the capsule.^{1,20,21} Transition stages of the disease are not separated for a certain period of time. As in previous studies with the immobilization model, there is no synovial flattening in the axillary fold as well as capsular thickening and additional inflammatory cell-like appearance.

In the literature, there are studies to determine when and how the histology of the joint capsule is changed during the development of the animal frozen shoulder model.^{6,7} In these studies, the pathological changes in the capsule started 3 weeks after immobilization and shoulder joint restriction completed without increasing at the end of eight weeks. These findings in an experimental model correspond to the clinical second stage of adhesive capsulitis. There is a consensus that non-operative management is the initial treatment for adhesive capsulitis and is recommended for six months.^{3,21} The use of corticosteroids in the treatment of adhesive capsulitis may lead to a faster increase of ROM and pain reduction. However, this treatment has no specific timing between periods for this condition.^{6,21,22} In our study, we preferred to start the drug effect on the disease after the recommended period in the previously described model. To the

Table 2. Histological investigation data of the groups

		Control	Sham	Natural course	Intraarticular	Oral
Capillary proliferation	Mean	12.13	17.00	11.25	12.75	9
	n	8	8	8	8	7
	Median	11.50	15.50	10.00	9	8
	Min	6	8	8	4	7
	Max	22	36	18	28	14
Fibroblast proliferation	Null	1	6	1	3	3
	Mild	7	2	7	4	3
	Severe	0	0	0	1	1
Collagen density	Null	0	1	0	0	0
	Mild	6	7	5	6	6
	Severe	2	0	3	2	1
Axillar pouch synovial curved structure	Ruffle curvature	1	5	4	5	1
	A few twists	2	1	3	2	3
	Flat	5	2	1	1	3
Capsule thickness	Mean	189.34	118.40	184.70	229.15	191.68
	n	8	8	8	8	7
	Median	165.56	91.27	152.78	217.11	195.22
	Min	56.68	57.55	129.49	92.31	117.48
	Max	340.65	335.35	323.94	372.05	262.03
Immunohistochemical type III collagen	Null	0	0	0	0	0
	Mild	7	6	6	7	5
	Severe	1	2	2	1	1

best of our knowledge, the effects of the application of corticosteroid in adhesive capsulitis has not been reported in the experimental models.

Kinematic evaluation of the shoulder joint was examined by the methods specified in the previously published studies in the literature.^{6,10} The joint ROM values measured for each group were determined in the in vitro setting. The degree of ROM of the shoulder joint was significantly lower in the control (disease model) group compared to the sham (healthy) group. This finding confirmed that the frozen shoulder model was successfully created. In addition, although the abduction angle increased compared to the group in which the course of the condition course was formed, the rats followed in its natural course did not increase sufficiently in the angle of rotation. Thus, this modeling was shown to be compatible with the natural course of ac disease. Compared to the sham (healthy) group, the shoulder ROM of the natural course group was significantly lower in all directions. Therefore, sacrifice of the rat shoulder joint 2 weeks after its release is appropriate to observe the healing status in the groups in which we examined the success of the treatment and, although not as well as the healthy group.

Among the treatment groups, a better abduction angle was obtained in IA cortisone administration compared to oral administration, and significantly better results were obtained from the natural course group, although not in the healthy group. In clinically frozen shoulder disease, the most obvious limitation in joint ROM is in the direction of external rotation, while in the rat model it is known to be in the direction of abduction.^{7,8} It is thought that this difference may be due to the excessive use of abduction in the daily life of rats. In our study, the improvement in abduction direction in the groups in which improvement was investigated is an expected result, since it is the direction mostly used by the rats in shoulder movements during walking.

The direction in which the macroscopic sections (transverse, coronal) specimens are taken in the histopathological examination of the rat shoulder affects which anatomical structures are clearly visible. In coronal sections, pathological changes in the axilla cause a decrease in abduction movement. In rats, the most obvious limitation in frozen shoulder model is known to be in the direction of abduction. Kanno et al.⁶ reported that the most evident changes due to immobilization were seen in the axillary fold covered with a thick subsynovial tissue in the histopathological examination with a coronal section at Week 8. They described that synovial folds disappeared and became a flat surface in the immobilization group. Synovitis, inflammation, and synovial cell proliferation were not detected in the shoulder joint. These data are consistent with our findings. In the present study, we also measured the synovial intima structure and capsule thickness in the axillary fold and found that the synovial fold thickened and decreased in the disease model group compared to the sham group. *Albeit*, the axillary synovial folding structure was similar to the IA cortisone group and the sham group, there was no significant change between the treatment groups. Capillary proliferation, collagen density, and increased type III collagen evaluation in capsule and synovium are important parameters in the clinical histological evaluation of frozen shoulder disease, but in our experimental study, we did not find any significant difference between the groups histologically. Several authors have advocated that type III collagen is important in the development of capsular stiffness, but there are different opinions on this issue, and significant changes in collagen type III expression in the capsule after immobilization are still controversial.^{23,24} The lack

of type III collagen in periarticular connective tissue supports the concept that inflammation is not the basis of the contracture process, as type III collagen is almost always present with type I in inflammatory tissue.^{25,26} Although collagen deposition is the main component in scar tissue, we found a similar distribution among all groups in our study without a significant difference. Based on these findings, we consider that the pathological development process of frozen shoulder continues without scarring. Spontaneous resolution of the condition in its natural history may be related to this condition, as scarring is irreversible.

In the current study, we investigated the clinical and pathological effects of different uses of cortisone therapy on frozen shoulder disease in the in vitro setting. We compared the shoulder motion and histopathological findings after cortisone administration. The results showed that oral corticosteroid treatment in rats did not improve at a level to produce a significant difference from the disease model and it was not superior to the natural course and IA group. There are several studies reporting that a significant improvement and comparable results were obtained with both oral and IA cortisone application. Widyastuti-Samekto et al.¹⁴ compared oral and IA cortisone applications in Stage 2-3 frozen shoulder patients in a clinical study. Although they obtained a similar clinical result with both methods, they found only the IA corticosteroid treatment to be more successful than oral treatment, as it provided a return to work before. However, in their studies, the difference between the two groups was detected only in the 1st week, while similar results were obtained in terms of pain and ROM at the 3rd week. In addition, in a prospective study by Lorbach et al.,¹² three injections were given to the IA cortisone group and the both groups were examined at Weeks 4, 8, 12, 24, and 52. In this study, while Visual Analog Scale (VAS) scores were not different in terms of pain and function, satisfaction score was found to be significantly higher in the IA group starting from the Week 8. The superiority of success in clinical scores in the IA group was also determined in the ROM range data. Also, Canbolat et al.¹⁵ reported that oral glucocorticoid therapy combined with pregabalin was an effective treatment for patients with frozen shoulder. Due to the similar results obtained between the two treatment methods in the long term, there is still no complete clarity between the two methods, supporting our hypothesis. However, in our study, we found that IA corticosteroid therapy was superior in terms of gained ROM compared to oral therapy, but not histologically. Of note, both of these clinically applied methods have their pros and cons. In particular, IA cortisone application carries the risk of rare but serious joint infection.^{22,27} In addition, the use of oral cortisone should be followed closely for adverse effects.²⁸ Although the short-term effects of these applications are not frequent, the long-term effects are not yet known.

Nonetheless, there are some limitations to this study. The main limitation is that a primary frozen shoulder model was unable to be created. Another limitation is that we used only one drug dose. However, we believe that our study would pave the way for future studies which can be designed using different drug dosages, larger animal models, and different follow-up times. Similar to the fact that the transition timing between clinical periods cannot be clearly determined in frozen shoulder disease, there is uncertainty in experimental modeling. It may be beneficial to investigate the therapeutic efficacy at different immobilization time other than mentioned in previous studies. In addition, with further histopathological examination at the biochemical level, the effectiveness of cortisone can be examined in more detail.

In conclusion, we successfully developed an animal model simulating shoulder contracture by joint immobilization using internal fixation. Additionally, IA steroid injection was found to be superior in increasing the ROM compared to oral steroid treatment. The histopathological inconsistency of the clinical gain obtained with cortisone therapy in this disease can be evaluated as spontaneous recovery in the natural course of the disease. We believe that a single dose of IA cortisone therapy would be sufficient in this disease. With a good knowledge of pathogenesis, it would become easy to determine the treatment modalities that could improve objective and subjective measures in the disease course.

Ethics Committee Approval: Ethics Committee and Institutional Review Board approval were received for this study from the Başkent University (Project no: DA 16/12 [22/02/2016]).

Informed Consent: N/A.

Author Contributions: Concept - B.M.Ç.; Design - B.M.Ç.; Supervision - B.M.Ç.; Materials - V.E.B.; Data Collection and/or Processing - V.E.B., B.M.Ç.; Analysis and/or Interpretation - B.M.Ç.; Literature Review - B.M.Ç.; Writing - B.M.Ç., Ü.Ö.G.; Critical Review - B.M.Ç., Ü.Ö.G.; Experimental Executive - N.B., S.B.

Conflict of Interest: The authors have no conflicts of interest to declare.

Financial Disclosure: This study supported by Başkent University Research Fund.

References

- Hannafin A, Chiaia TA. Adhesive capsulitis: A treatment approach. *Clin Orthop Relat Res*. 2000;372:95-109. [10.1097/00003086-200003000-00012](#)
- Tamai K, Akutsu M, Yano Y. Primary frozen shoulder: Brief review of pathology and imaging abnormalities. *J Orthop Sci*. 2014;19(1):1-5. [10.1007/s00776-013-0495-x](#)
- Yip M, Francis AM, Roberts T, Rokito A, Zuckerman JD, Virk MS. Treatment of adhesive capsulitis of the shoulder a critical analysis review. *JBJS Rev*. 2018;6(6):e5. [10.2106/JBJS.RVW.17.00165](#)
- Hand GC, Athanasou NA, Matthews T, Carr AJ. The pathology of frozen shoulder. *J Bone Joint Surg Br*. 2007;89(7):928-932. [10.1302/0301-620X.89B7.19097](#)
- Ozaki J, Nakagawa Y, Sakurai G, Tamai S. Recalcitrant chronic adhesive capsulitis of the shoulder. Role of contracture of the coracohumeral ligament and rotator interval in pathogenesis and treatment. *J Bone Joint Surg Am*. 1989;71(10):1511-1515. [10.2106/00004623-198971100-00009](#)
- Kanno A, Sano H, Itoi E. Development of a shoulder contracture model in rats. *J Shoulder Elbow Surg*. 2010;19(5):700-708. [10.1016/j.jse.2010.02.004](#)
- Kim DH, Lee KH, Lho YM, et al. Characterization of a frozen shoulder model using immobilization in rats. *J Orthop Surg Res*. 2016 8;11(1):160. [10.1186/s13018-016-0493-8](#)
- Ochiai N, Ohtori S, Kenmoku T, et al. Sensory innervation of rat contracture shoulder model. *J Shoulder Elbow Surg*. 2013;22(2):158-164. [10.1016/j.jse.2012.02.011](#)
- Okii S, Shirasawa H, Yoda M, et al. Generation and characterization of a novel shoulder contracture mouse model. *J Orthop Res*. 2015;33(11):1732-1738. [10.1002/jor.22943](#)
- Villa-Camacho JC, Okajima S, Perez Vilorio M, et al. In vivo kinetic evaluation of an adhesive capsulitis model in rats. *J Shoulder Elbow Surg*. 2015;24(11):1809-1816. [10.1016/j.jse.2015.06.015](#)
- Buchbinder R, Green S, Youd JM. Corticosteroid injections for shoulder pain. *Cochrane Database Syst Rev*. 2003;2003(1):CD004016.
- Lorbach O, Anagnostakos K, Scherf C, Seil R, Kohn D, Pape D. Nonoperative management of adhesive capsulitis of the shoulder: Oral cortisone application versus intra-articular cortisone injections. *J Shoulder Elbow Surg*. 2010;19(2):172-179. [10.1016/j.jse.2009.06.013](#)
- Song A, Higgins LD, Newman J, Jain NB. Glenohumeral corticosteroid injections in adhesive capsulitis: A systematic search and review. *PM R*. 2014;6(12):1143-1156. [10.1016/j.pmrj.2014.06.015](#)
- Widiastuti-Samekto M, Sianturi GP. Frozen shoulder syndrome: Comparison of oral route corticosteroid and intra-articular corticosteroid injection. *Med J Malaysia*. 2004;59(3):312-316.
- Canbulat N, Eren I, Atalar AC, et al. Nonoperative treatment of frozen shoulder: Oral glucocorticoids. *Int Orthop*. 2015;39(2):249-254. [10.1007/s00264-014-2650-1](#)
- Atıcı T, Ermutlu C, Akesen A, Özyalcın A. High-dose short-course oral corticosteroid protocol for treatment of primary Frozen shoulder: A retrospective cohort study. *J Int Med Res*. 2021;49(7):1-13. [10.1177/03000605211024875](#)
- Kong AN, Jusko WJ. Disposition of methylprednisolone and its sodium succinate prodrug in vivo and in perfused liver of rats: Nonlinear and sequential first-pass elimination. *J Pharm Sci*. 1991;80(5):409-415. [10.1002/jps.2600800502](#)
- Schollmeier G, Uthoff HK, Sarkar K, Fukuhara K. Effects of immobilization on the capsule of the canine glenohumeral joint. A Structural Functional Study. *Clin Orthop Relat Res*. 1994;(304):37-42.
- Schollmeier G, Sarkar K, Fukuhara K, Uthoff HK. Structural and functional changes in the canine shoulder after cessation of immobilization. *Clin Orthop Relat Res*. 1996;323:310-315. [10.1097/00003086-199602000-00044](#)
- Bunker TD, Anthony PP. The pathology of frozen shoulder. a Dupuytren-like disease. *J Bone Joint Surg Br*. 1995;77(5):677-683. [10.1302/0301-620X.77B5.7559688](#)
- Cinar M, Akpınar S, Derincek A, Circi E, Uysal M. Comparison of arthroscopic capsular release in diabetic and idiopathic frozen shoulder patients. *Arch Orthop Trauma Surg*. 2010;130(3):401-406. [10.1007/s00402-009-0900-2](#)
- Eustace JA, Brophy DP, Gibney RP, Bresnihan B, FitzGerald O. Comparison of the accuracy of steroid placement with clinical outcome in patients with shoulder symptoms. *Ann Rheum Dis*. 1997;56(1):59-63. [10.1136/ard.56.1.59](#)
- Liu YL, Ao YF, Cui GQ, Zhu ZX. Changes of histology and capsular collagen in a rat shoulder immobilization model. *Chin Med J (Engl)*. 2011;124(23):3939-3944.
- Matsumoto F, Trudel G, Uthoff HK. High collagen type I and low collagen type III levels in knee joint contracture: An immunohistochemical study with histological correlate. *Acta Orthop Scand*. 2002;73(3):335-343. [10.1080/000164702320155365](#)
- Amiel D, Akeson WH, Harwood FL, Mechanic GL. The effect of immobilization on the types of collagen synthesized in periarticular connective tissue. *Connect Tissue Res*. 1980;8(1):27-32. [10.3109/03008208009152118](#)
- Hagiwara Y, Ando A, Onada Y, et al. Expression patterns of collagen types I and III in the capsule of a rat knee contracture model. *J Orthop Res*. 2010;28(3):315-321. [10.1002/jor.20997](#)
- Maman E, Yehuda C, Pritsch T, et al. Detrimental effect of repeated and single subacromial corticosteroid injections on the intact and injured rotator cuff: A biomechanical and imaging study in rats. *Am J Sports Med*. 2016;44(1):177-182. [10.1177/0363546515591266](#)
- Walsh LJ, Wong CA, Osborne J, et al. Adverse effects of oral corticosteroids in relation to dose in patients with lung disease. *Thorax*. 2001;56:279-284. [10.1136/thorax.56.4.279](#)