




Contents lists available at ScienceDirect

## Acta Orthopaedica et Traumatologica Turcica

journal homepage: <https://www.elsevier.com/locate/aott>

## Comparison of clavicular hook plate with and without coracoclavicular suture fixation for acute acromioclavicular joint dislocation



Hao-Ming Chang<sup>a</sup>, Chih-Kai Hong<sup>a</sup>, Wei-Ren Su<sup>a,b</sup>, Tzu-Hao Wang<sup>c</sup>, Chih-Wei Chang<sup>a</sup>, Ta-Wei Tai<sup>a,b,\*</sup>

<sup>a</sup> Department of Orthopaedic Surgery, National Cheng Kung University Hospital, College of Medicine, National Cheng Kung University, Tainan, Taiwan

<sup>b</sup> Skeleton Materials and Bio-compatibility Core Lab, Research Center of Clinical Medicine, National Cheng Kung University Hospital, College of Medicine, National Cheng Kung University, Tainan, Taiwan

<sup>c</sup> Municipal Min-Sheng Hospital, Kaohsiung, Taiwan

### ARTICLE INFO

#### Article history:

Received 13 September 2018

Received in revised form

23 April 2019

Accepted 22 August 2019

Available online 30 September 2019

#### Keywords:

Acromioclavicular joint

Acromioclavicular dislocation

Hook plate

Coracoclavicular augmentation

Shoulder

### ABSTRACT

**Objective:** The aim of this study was to compare the clinical and radiographic outcomes of clavicular hook plate fixation with and without coracoclavicular (CC) tape augmentation for the treatment of acute unstable AC dislocation.

**Methods:** We treated 47 patients (31 men and 16 women; mean age: 47 years (range, 21–81)) with unstable acute AC dislocations (Rockwood III–V) and divided them into two groups according to the treatment modality, with hook plate fixation (hook plate group) or hook plate plus CC tape augmentation (combined group). We assessed radiologic findings, such as subacromial osteolysis and AC osteoarthritis. We also evaluated the clinical outcomes using a visual analogue scale (VAS) for pain, as well as the University of California at Los Angeles (UCLA) Shoulder Rating Scale and the American Shoulder and Elbow Surgeons (ASES) Shoulder Score.

**Results:** We found that the combined group had less subacromial osteolysis upon radiography, although the CC distance was similar in both groups ( $119 \pm 29.7\%$  of contralateral side CC distance in hook plate group versus  $119 \pm 34.8\%$  in the combined group,  $p = 0.77$ ). Compared with the hook plate group, the combined group had a lower VAS score ( $4.5 \pm 2.3$  in hook plate group versus  $2.3 \pm 1.4$  in the combined group,  $p < 0.001$ ), better UCLA scores ( $19.9 \pm 4.9$  in hook plate group versus  $27.2 \pm 4.0$  in the combined group,  $p < 0.001$ ) as well as better ASES scores ( $51.9 \pm 17.8$  in hook plate group versus  $73.8 \pm 13.1$  in the combined group,  $p < 0.001$ ) at 3 and 6 months after surgery.

**Conclusion:** Hook plate fixation plus CC tape augmentation may prevent subacromial osteolysis and yield better short-term functional outcomes.

**Level of Evidence:** Level III, Therapeutic Study.

© 2019 Turkish Association of Orthopaedics and Traumatology. Publishing services by Elsevier B.V. This is an open access article under the CC BY-NC-ND license (<http://creativecommons.org/licenses/by-nc-nd/4.0/>).

### Introduction

Acromioclavicular (AC) joint dislocation is a common injury and accounts for 9% of shoulder girdle injuries.<sup>1</sup> Although there is a high

prevalence of AC dislocation, the best management for acute AC dislocation remains controversial. The surgical treatment of AC dislocations include AC joint fixation (with pin, screw, suture wire, and hook plate),<sup>2</sup> coracoclavicular (CC) screw fixation,<sup>3</sup> ligament transfer, and ligament reconstruction. Using a clavicle hook plate is one of the most popular ways to treat this condition; it is a simple and effective treatment.<sup>4</sup> There are many studies reporting good functional score and imaging analysis after treatment with clavicle hook plates.<sup>2,4,5</sup> Many physicians preferred the hook plate as the first treatment choice for acute AC dislocations.<sup>6</sup> However, there are

\* Corresponding author. Department of Orthopaedics, National Cheng Kung University Hospital, College of Medicine, National Cheng Kung University, 138 Sheng-Li Road, Tainan 70428, Taiwan.

E-mail address: [david0803@gmail.com](mailto:david0803@gmail.com) (T.-W. Tai).

Peer review under responsibility of Turkish Association of Orthopaedics and Traumatology.

still some complications reported after clavicular hook plate fixation. The reported complications included, early limited range of motion (ROM) of the shoulder,<sup>7</sup> subacromial erosion,<sup>8–10</sup> peri-implant fractures,<sup>11</sup> acromion cut-out,<sup>9,12</sup> rotator cuff impingement,<sup>13</sup> and permanent shoulder pain.<sup>14</sup> Most implants required removal because of the irritation and the above complications.

Previous studies also showed that CC cerclage augmentation could provide dynamic fixation through the healing process.<sup>8,15,16</sup> After the restoration of pre-injury CC tensile strength, the CC ligaments heals gradually.<sup>17</sup> However, the most common problem with these techniques was the weak initial fixation. The failure of fixation led to re-dislocation.<sup>15</sup>

Several studies supports the combined treatment of AC fixation and CC augmentation. Kirschner wire transfixation of the AC joint combined with Vicryl tape suture augmentation for the CC joint revealed good clinical results.<sup>18</sup> The other case series showed that clavicular hook plate fixation combined with CC suture anchor augmentation achieved satisfactory outcomes for patients with chronic AC dislocations.<sup>19</sup>

The benefits of combined AC fixation and CC augmentation include initial strong fixation and persistent support by CC augmentation after removal of AC fixation implants. This combined treatment allowed early rehabilitation and reduced the risk of re-dislocation, theoretically. However, there is no published evidence comparing clavicular hook plate fixation with or without CC augmentation. The aim of this study was to investigate the role of CC tape augmentation in patients who received hook plate fixation for AC dislocations. We hypothesized that clavicle hook plate fixation with CC tape augmentation for the treatment of acute unstable AC joint dislocation would provide better clinical and radiographic outcomes than treatment with the hook plate alone.

## Materials and methods

We included the patients with acute AC joint dislocations (Rockwood III–V) who were managed at our hospital from August 2014 to March 2017. The patients' demographics were presented in Table 1.

### Participants

We reviewed consecutive cases of AC dislocation in a single center. The inclusion criteria were (1) acute (injury less than 2 weeks) AC dislocation (Rockwood type III and V), (2) having been treated with hook plate with or without CC tape augmentation, and (3) having been followed-up for at least 9 months post-surgery. The exclusion criteria were (1) existing history of bone disease, (2) previous shoulder surgery, (3) previous or combined fracture of the clavicle, scapula, or humerus, (4) previous AC joint lesion, and (5)

history of ipsilateral shoulder movement limitation, (6) other concomitant shoulder injury.

### Surgical procedure

Experienced trauma surgeons performed all the procedures. Patients underwent the operation with general anaesthesia in the beach chair position with freely mobile injured limbs. A skin incision was made superior to the clavicle followed by an incision of the deltotrapezoid fascia. We reduced the AC joint by direct visualization. All the patients received hook plate fixation after proper reduction of the AC joint. To perform CC tape augmentation or not depended on surgeon's preference. In patients who received combined hook plate fixation with CC tape augmentation (combined group), a non-absorbable, braided, sterile polyester surgical tape (Mersilene® Polyester Fiber Suture, Ethicon, Cincinnati, OH, USA) was passed inferiorly to the coracoid process with right-angle forceps and was tied firmly with multiple knots anterior to the clavicle. Then, an appropriately sized hook plate (Aplus® Distal Clavicle HOOK Locking Plate System, Aplus, Taipei, Taiwan) was chosen and inserted postero-inferiorly to the acromion followed by fixation with several clavicle locking screws [Fig. 1A,B]. For patients who received hook plate fixation alone (hook plate group), the CC space was not exposed. We used absorbable suture to repair AC joint capsule after plate and tape fixation. We confirmed the correct position of the plate and the AC joint position with fluoroscope images. The deltotrapezoid fascia was repaired with Vicryl 2-0 absorbable suture.

### Postoperative care

After the operation, we advised the patients to wear sling protection for 2 weeks followed by progressive rehabilitation programmes. In the first 2 weeks, passive range of motion (abduction, forward elevation, and circle motion up to 60°) was done by the physiotherapists. Pendulums exercise was instructed as the home exercise program. The goal of active assisted abduction and elevation is 90° in 6 weeks after surgery. Tolerable movement was allowed at 6 weeks postoperatively including daily activity. Abduction and elevation more than 90° is neither restricted nor encouraged. Progressive strengthening activities were permitted at 6 weeks postoperatively. The hook plates were removed at 6 months postoperatively.

### Radiological and clinical outcomes

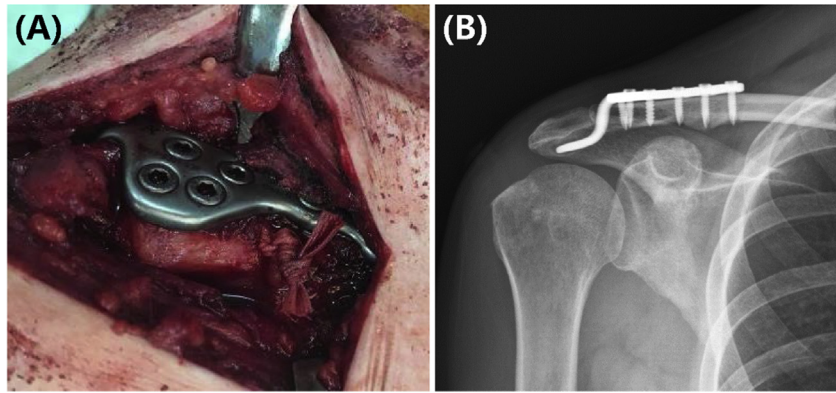
One independent observer who was blinded with the treatment performed the clinical assessments. For radiological outcomes, we standardized the radiologic assessment with bilateral shoulder anteroposterior view images. We evaluated the coracoclavicular distance (CCD, the height in percentage compared to the contralateral shoulder between the upper border of the coracoid process and the inferior cortex of the clavicle) [Fig. 2]. Compared to the contralateral side, the subluxation was defined as CCD > 150%. We graded the subacromial osteolysis in the radiography as I: minimal osteolysis, II: osteolysis <2 mm, III: osteolysis >2 mm, and IV: cut-through of the acromion. AC joint osteoarthritis was also recorded.

For clinical outcomes, we analysed preoperative, 3-month postoperative, 6-month postoperative (before the removal of the implants) and final follow-up (9–27 months) clinical and radiographic outcomes. In the clinical outcome, we used the visual analogue scale (VAS) for pain assessment, the University of California at Los Angeles (UCLA) Shoulder Rating Scale, and the American Shoulder and Elbow Surgeons Shoulder Score (ASES) to

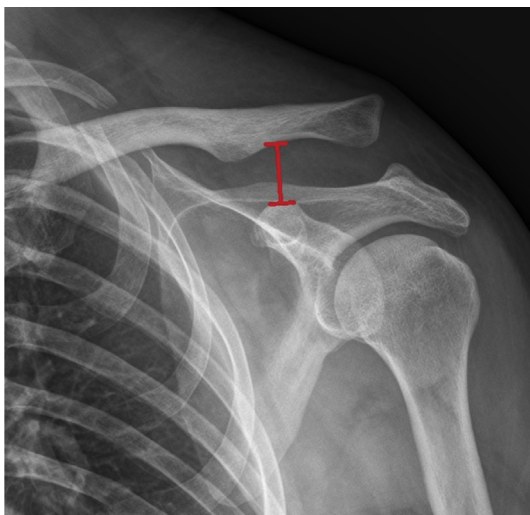
**Table 1**  
Participant demographic data.

	Hook plate group	Combined group
Patient number	26	21
Age	50 (24–69)	44 (21–81)
Gender	M: 16; F: 10	M: 15; F: 6
Injured side	Dominant: 16 Non-dominant: 10	Dominant: 9 Non-dominant: 12
Rockwood Type	III: 12; V: 14	III: 7; V: 14
Operation time (minutes)*	46 (30–90)	80 (41–115)
Implant removal time (postoperative months)	6 (3–12)	6 (5–10)
Follow-up time (months)	11 (9–27.1)	9.5 (9–11.4)

Data are presented as the median (range). \* $p < 0.05$ .



**Fig. 1.** (A) Hook plate fixation with coracoclavicular augmentation with Mersilene tape #5 for acute acromioclavicular dislocation. (B) Immediate postoperative radiograph showed AC joint dislocation was well-reduced with hook plate fixation.



**Fig. 2.** The measurement of the coracoclavicular distance (CCD) in radiograph.

evaluate individual postoperative satisfaction in the different periods.

#### Statistical analysis

We used the Mann–Whitney U test for between-group comparisons of the parameters of radiographic findings and clinical functional outcomes. Significance was set at  $p < 0.05$ . The statistical

testing was performed by using SPSS version 17.0 software (SPSS, Chicago IL, USA).

#### Results

A total of 51 patients with acute AC joint dislocations (Rockwood III–V) were managed at our hospital from August 2014 to March 2017, and 47 patients (31 male and 16 female) who underwent clavicle hook plate fixation with and without CC augmentation were enrolled in the study. The median age was 47 years old (range: 21–81) (Table 1). Twenty-four patients (51%) injured their dominant extremities. Thirty-four patients (72.3%) were injured in a traffic accident, and 13 (27.7%) were hurt after falling down. The final clinical and radiologic assessments were performed after a mean of 10.9 months (ranged 9–27 months). There were 19 (40.4%) AC dislocations categorized as Rockwood classification type III and 28 (59.6%) as type V. Twenty-six patients underwent open reduction and internal fixation with the hook plate alone (hook plate group); twenty-one patients underwent hook plate fixation plus CC tape augmentation (combined group). The median operation time was 46 min in the hook plate group and 80 min in the combined group ( $p < 0.05$ ). All the patients underwent removal of the implants. The mean time of the removal of hook plates after the primary surgery was  $6.7 \pm 2.2$  months in the hook plate group and  $6.2 \pm 1.0$  months in the combined group.

A radiological analysis showed that the combined group had less severe subacromial osteolysis (grade III and IV) than the hook plate groups ( $p = 0.02$ , Chi-square test) (Table 2). There was no significant difference of CCD on the radiograms between two groups in preoperative, postoperative, and post-implant removal, as well as

**Table 2**  
Participant radiographic outcomes.

	Hook plate group	Combined group	Statistics
Coracoclavicular distance (CCD, % of contralateral side)			
Preoperatives	202.4 $\pm$ 54.5%	222.0 $\pm$ 56.5%	$p = 0.346$
Postoperative	65.7 $\pm$ 26.8%	71.2 $\pm$ 22.6%	$p = 0.257$
Before removal of implants	90.5 $\pm$ 33.3%	85.6 $\pm$ 35.1%	$p = 0.716$
Final follow-up	118.9 $\pm$ 29.7%	118.9 $\pm$ 34.8%	$p = 0.767$
Grading of Subacromial osteolysis			
Mild			$p = 0.02^a$
I (minimal osteolysis)	5	8	
II (depression < 2 mm)	6	8	
Significant			
III (depression > 2 mm)	13	5	
IV (cut-out of acromion)	2	0	
AC joint arthritis	8 (30.8%)	3 (14.3%)	$p = 0.164$

<sup>a</sup> Significant difference in Chi square test.

**Table 3**  
Coracoclavicular distance (CCD) at final follow-up.

	Hook plate group	Combined group	Statistics <sup>c</sup>
Over-reduction (CCD < 100% <sup>a</sup> )	8 (30.8%)	11 (52.4%)	$p = 0.609$
Adequate reduction (CCD = 100–150% <sup>a</sup> )	16 (61.5%)	8 (38.1%)	
Subluxation (CCD > 150% <sup>a</sup> )	2 (7.7%) <sup>b</sup>	2 (9.5%)	

<sup>a</sup> Compared to contralateral side CCD.<sup>b</sup> Included 2 acromion cut-out.<sup>c</sup> Chi-square test.

the final follow-up stage. We found 11 patients with arthritic changes at the AC joint. Eight (30.8%) of these patients were in the hook plate group and 3 (14.3%) in the combined group. There was a trend that the combined group had less chance of AC arthritis ( $p = 0.164$ ). For the radiographic findings at the final follow-up, most patients showed good status of anatomical position. Both groups had 2 cases of subluxation. There was no significant difference between the two groups ( $p = 0.609$ ) (Table 3).

The combined group showed less pain at 3 and 6 months after surgery (Table 4). The VAS score was significantly lower than the hook plate group ( $3.4 \pm 1.4$  versus  $5.2 \pm 1.8$  in 3 months and  $2.3 \pm 1.4$  versus  $4.5 \pm 2.3$  in 6 months). However, the two groups showed no difference in pain score in the final follow-up.

The combined group also showed significantly better functional outcomes at 3 and 6 months after surgery. Both UCLA and ASES scores were better in the combined group than in the hook plate group. However, there was no difference at the final follow-up. The return to work time was  $4.3 \pm 2.8$  months in the hook plate group and  $4.2 \pm 2.3$  months in the combined group, with no significant difference ( $p = 0.85$ ).

Two patients in the hook plate group had complications with acromial cut-through. These patients underwent revision surgery to repair the acromion and re-fix the AC joints. One patient in the hook plate group had a superficial wound infection treated with oral antibiotics. No neurovascular injury was noted in our cohort.

## Discussion

This is the first study to compare functional and radiographic outcomes between hook plate fixation with and without CC augmentation for acute AC dislocation. We found that hook plate fixation plus CC tape augmentation showed less pain and better functional scores at 3 and 6 months after surgery. This combined treatment also showed less subacromial osteolysis and fewer complications at the final follow-up.

**Table 4**  
Postoperative functional scores in the hook plate and combined groups at different periods after the index procedure.

	Hook plate group	Combined group	Statistics
VAS			
3 months	$5.2 \pm 1.8$	$3.4 \pm 1.4$	$p = 0.001^a$
6 months	$4.5 \pm 2.3$	$2.3 \pm 1.4$	$p < 0.001^a$
Final follow-up	$1.5 \pm 1.4$	$1.1 \pm 1.2$	$p = 0.171$
UCLA score			
3 months	$15.9 \pm 4.6$	$23.0 \pm 2.9$	$p < 0.001^a$
6 months	$19.9 \pm 4.9$	$27.2 \pm 4.0$	$p < 0.001^a$
Final follow-up	$31.6 \pm 3.9$	$33.5 \pm 1.7$	$p = 0.072$
ASES score			
3 months	$40.0 \pm 14.2$	$61.4 \pm 9.7$	$p < 0.001^a$
6 months	$51.9 \pm 17.8$	$73.8 \pm 13.1$	$p < 0.001^a$
Final follow-up	$87.7 \pm 11.2$	$92.1 \pm 7.2$	$p = 0.176$
Return to work (months)	$4.3 \pm 2.8$	$4.2 \pm 2.3$	$p = 0.850$

<sup>a</sup> Significant difference in Mann–Whitney test.

Nonsurgical management of patients with type III injuries may also yield acceptable results.<sup>20–22</sup> However, persistent pain and residual symptoms after conservative treatment were also reported in the literature.<sup>23–25</sup> Thus, some authors advise surgical fixation for acute type III acromioclavicular joint injuries, especially in young and active patients, to improve outcomes.<sup>26–28</sup> Surgical treatment for type III AC dislocation offers better subjective and cosmetic results than conservative treatment in young active patients.<sup>29</sup>

Some previous studies used tension bands and Kirschner wires applied through the acromioclavicular joint<sup>2,30</sup> and extraarticular Bosworth screws to maintain reduction.<sup>3,31</sup> However, loosening or breakage of the implants was reported after surgery because of stress concentration and non-dynamic fixation.<sup>2,32</sup> The clavicular hook plate works by generating a leverage force through the proximal end of the plate to the acromion as a dynamic fixation and can maintain clavicle position and CC distance to achieve satisfying results.<sup>30,33,34</sup> One study showed that hook plate fixation is the closest method to the normal biomechanics of the AC joint.<sup>35</sup>

Hook plate fixation became one of the popular techniques for the treatment of AC joint dislocation. Many surgeons favoured this technique to fix Rockwood type III to VI AC dislocation.<sup>6</sup> However, despite mechanical stability as its primary advantage, some recent studies reported that there are some notable disadvantages, such as subacromial impingement, limited early range of motion,<sup>7</sup> rotator cuff impingement,<sup>13</sup> subacromial erosion,<sup>8–10</sup> peri-implant fractures,<sup>11</sup> and acromion cut-through.<sup>9,12</sup>

A previous cadaveric study mentioned that the CC sling with Mersilene tape #5, one of the fixations of AC dislocation, was significantly less stiff than the normal joint or the other fixation method.<sup>35</sup> One study showed that Kirschner wire transfixation of the AC joint combined with suture of the CC ligaments could obtain satisfactory results and maintain AC reduction.<sup>18</sup> The other case series also showed that clavicular hook plate combined with a suture anchor would achieve satisfactory outcomes.<sup>19</sup> One cadaveric study mentioned that the CC augmentation with Mersilene tape #5 may help to maintain clavicular position.<sup>35</sup> These studies suggested that combined treatment with AC fixation and CC augmentation might be a good choice.

Augmentation with CC tape needs more soft tissue dissection. It is possible to lead more pain in the early post-operative days, but it did not prolong the hospital stay in our series. It suggested the additional acute pain resulting from CC space dissection was acceptable and tolerable.

Although there was no difference between groups regarding the CCD after surgery, we found more severe osteolysis in the hook plate group. In the combined group, the tape shared the loading of the acromion. In this situation, the hook may also reduced irritation to the acromion and trigger less osteolytic changes. Theoretically, CC tape augmentation is possible to reduce the risk of acromial cut-through. More studies are required to address this issue.

We found two cases of cut-through after hook plate fixation. Acromial cut-through is a common complication after hook plate fixation.<sup>9,12,36,37</sup> The incidence of subacromial osteolysis after hook

plate fixation varied from 2.6% to 54.1%<sup>5,8,12,38,39</sup> and the complication of acromial cut-through was reported in several studies.<sup>9,12,36,37,40</sup> In our study, the incidence of subacromial osteolysis is approximately 27.7% (13 in 47), including two cases of acromial cut-through. Subacromial osteolysis and acromial cut-through are thought to be related to the stress overload on the acromion,<sup>41</sup> surgical techniques,<sup>42</sup> and the hook plate design.<sup>43</sup> Some authors suggested that patients should be instructed to avoid forward flexion or abduction greater than 90° as well as internal rotation of the shoulder behind the back.<sup>37</sup> Another study recommended that shoulder motion should be restricted until plate removal.<sup>44</sup> The hook plate was not recommended for use in patients who could not follow a restricted activity rehabilitation protocol.<sup>36</sup> However, a retrospective study revealed that the occurrence of subacromial osteolysis does not significantly affect shoulder function after plate removal.<sup>39</sup>

We found less pain and better early functional outcomes after hook plate fixation with CC tape augmentation. Compared with the patients undergoing hook plate fixation only, the patients felt better less than 6 months after surgery. However, both groups showed similar results at the final follow-up. This result implied that even though longer operation time and more dissection to pass the CC tape were noted in the combined groups, the CC augmentation provided pressure distribution from subacromial surface to coracoid process and further stability to reduce the hook plate irritation, which may lead to better early functional outcomes before hook plate removal. There was no difference in the return to work time. Additional CC augmentation provided better short-term outcomes but required more surgical time. The surgeon should make decision individually according each patient's condition.

Currently, there are various surgical techniques and implants to stabilize AC joint dislocation. None of current techniques has showed superior to the others.<sup>8,28,45–50</sup> Because the traditional fixation methods may lead to residual pain, inferior shoulder function and inadequate remaining instability,<sup>47–51</sup> some authors suggested using button and rope system for fixation.<sup>52,53</sup> The double double-button suture CC-stabilizing reduced pain and yielded better functional results than hook plate fixation.<sup>53</sup>

This study has some limitations. First, this is a retrospective study, and there may be selection bias after excluding patients with incomplete records. However, this is the first study to compare hook plate with and without CC augmentation. We carefully excluded patients with incomplete records. The demographic data of the included patients showed no difference between groups. Second, the long-term results were unavailable. However, the radiographic and functional outcomes at the final follow-up (average 10.9 months) already showed no significant difference between groups. We believe that CC tape augmentation only brings short-term benefits.

## Conclusion

Compared with fixation with the hook plate only, combined hook plate fixation with CC tape augmentation to treat acute AC dislocation may yield less pain and provide better short-term clinical outcomes and less subacromial osteolysis.

## Ethical approval

The study protocol was approved by the Institutional Review Board of National Cheng Kung University Hospital (IRB: A-ER-106-111).

## Funding

There is no funding source.

## Conflicts of interest

All authors declare that they have no conflict of interest.

## Informed consent to participate

Not applicable.

## Acknowledgement

We are grateful to Skeleton Materials and Bio-compatibility Core Lab, Research Center of Clinical Medicine, National Cheng Kung University Hospital, for the assistance of this study.

## References

- Mazzocca AD, Arciero RA, Bicos J. Evaluation and treatment of acromioclavicular joint injuries. *Am J Sports Med.* 2007;35(2):316–329.
- Johansen JA, Grutter PW, McFarland EG, Petersen SA. Acromioclavicular joint injuries: indications for treatment and treatment options. *J Shoulder Elbow Surg.* 2011;20(2 Suppl):S70–S82.
- Kuchenreuter G. Experiences in the nailing of dislocations of the acromioclavicular joint according to Bosworth. *Chirurg.* 1956;27(6):250–252.
- Di Francesco A, Zoccali C, Colafarina O, Pizzoferrato R, Flamini S. The use of hook plate in type III and V acromio-clavicular Rockwood dislocations: clinical and radiological midterm results and MRI evaluation in 42 patients. *Injury.* 2012;43(2):147–152.
- Kumar N, Sharma V. Hook plate fixation for acute acromioclavicular dislocations without coracoclavicular ligament reconstruction: a functional outcome study in military personnel. *Strategies Trauma Limb Reconstr.* 2015;10(2):79–85.
- Balke M, Schneider MM, Akoto R, Bathis H, Bouillon B, Banerjee M. Acute acromioclavicular joint injuries. Changes in diagnosis and therapy over the last 10 years. *Unfallchirurg.* 2015;118(10):851–857.
- Arirachakaran A, Boonard M, Piyapittayanun P, et al. Post-operative outcomes and complications of suspensory loop fixation device versus hook plate in acute unstable acromioclavicular joint dislocation: a systematic review and meta-analysis. *J Orthop Traumatol.* 2017;18(4):293–304.
- Eschler A, Grادل G, Gierer P, Mittlmeier T, Beck M. Hook plate fixation for acromioclavicular joint separations restores coracoclavicular distance more accurately than PDS augmentation, however presents with a high rate of acromial osteolysis. *Arch Orthop Trauma Surg.* 2012;132(1):33–39.
- Hoffler CE, Karas SG. Transacromial erosion of a locked subacromial hook plate: case report and review of literature. *J Shoulder Elbow Surg.* 2010;19(3):e12–e15.
- Yoon JP, Lee BJ, Nam SJ, et al. Comparison of results between hook plate fixation and ligament reconstruction for acute unstable acromioclavicular joint dislocation. *Clin Orthop Surg.* 2015;7(1):97–103.
- Charity RM, Haidar SG, Ghosh S, Tillu AB. Fixation failure of the clavicular hook plate: a report of three cases. *J Orthop Surg (Hong Kong).* 2006;14(3):333–335.
- Zhu YY, Cui HY, Jiang PQ, Wang JL. Complications of treatment of acromioclavicular joint dislocation and unstable distal clavicular fracture with clavicular hook plate. *Zhongguo Gu Shang.* 2013;26(11):927–931.
- Lin HY, Wong PK, Ho WP, Chuang TY, Liao YS, Wong CC. Clavicular hook plate may induce subacromial shoulder impingement and rotator cuff lesion—dynamic sonographic evaluation. *J Orthop Surg Res.* 2014;9(1):6.
- Menge TJ, Boykin RE, Bushnell BD, Byram IR. Acromioclavicular osteoarthritis: a common cause of shoulder pain. *South Med J.* 2014;107(5):324–329.
- Greiner S, Braunsdorf J, Perka C, Herrmann S, Scheffler S. Mid to long-term results of open acromioclavicular-joint reconstruction using polydioxanulfate cerclage augmentation. *Arch Orthop Trauma Surg.* 2009;129(6):735–740.
- Stam L, Dawson I. Complete acromioclavicular dislocations: treatment with a Dacron ligament. *Injury.* 1991;22(3):173–176.
- Luis GE, Yong CK, Singh DA, Sengupta S, Choon DS. Acromioclavicular joint dislocation: a comparative biomechanical study of the palmaris-longus tendon graft reconstruction with other augmentative methods in cadaveric models. *J Orthop Surg Res.* 2007;2(1):22.
- Blatter G, Meier G. Augmentation of the coraco-clavicular ligament suture. Comparison between wire cerclage, vicryl tape and PDS cord. *Unfallchirurg.* 1990;93(12):578–583.
- Xu ZB, Wang J. Clavicular hook plate combined with suture anchor for the treatment of type Tossy III chronic acromioclavicular dislocation. *Zhongguo Gu Shang.* 2014;27(5):430–432.

20. Rolf O, Hann von Weyhern A, Ewers A, Boehm TD, Gohlke F. Acromioclavicular dislocation Rockwood III-V: results of early versus delayed surgical treatment. *Arch Orthop Trauma Surg.* 2008;128(10):1153–1157.
21. Bjerneld H, Hovelius L, Thorling J. Acromio-clavicular separations treated conservatively. A 5-year follow-up study. *Acta Orthop Scand.* 1983;54(5):743–745.
22. Taft TN, Wilson FC, Oglesby JW. Dislocation of the acromioclavicular joint. An end-result study. *J Bone Joint Surg Am.* 1987;69(7):1045–1051.
23. Mouhsine E, Garofalo R, Crevoisier X, Farron A. Grade I and II acromioclavicular dislocations: results of conservative treatment. *J Shoulder Elbow Surg.* 2003;12(6):599–602.
24. Schlegel TF, Burks RT, Marcus RL, Dunn HK. A prospective evaluation of untreated acute grade III acromioclavicular separations. *Am J Sports Med.* 2001;29(6):699–703.
25. Wojtys EM, Nelson G. Conservative treatment of grade III acromioclavicular dislocations. *Clin Orthop Relat Res.* 1991;268(1):112–119.
26. Ryhanen J, Niemela E, Kaarela O, Raatikainen T. Stabilization of acute, complete acromioclavicular joint dislocations with a new C hook implant. *J Shoulder Elbow Surg.* 2003;12(5):442–445.
27. Gstettner C, Tauber M, Hitzl W, Resch H. Rockwood type III acromioclavicular dislocation: surgical versus conservative treatment. *J Shoulder Elbow Surg.* 2008;17(2):220–225.
28. Lizaur A, Sanz-Reig J, Gonzalez-Parreno S. Long-term results of the surgical treatment of type III acromioclavicular dislocations: an update of a previous report. *J Bone Joint Surg Br.* 2011;93(8):1088–1092.
29. Korsten K, Gunning AC, Leenen LP. Operative or conservative treatment in patients with Rockwood type III acromioclavicular dislocation: a systematic review and update of current literature. *Int Orthop.* 2014;38(4):831–838.
30. Folwaczny EK, Yakisan D, Sturmer KM. The Balsler plate with ligament suture. A dependable method of stabilizing the acromioclavicular joint. *Unfallchirurg.* 2000;103(9):731–740.
31. Cetinkaya E, Arikan Y, Beng K, Mutlu H, Yalcinkaya M, Uzumcugil O. Bosworth and modified Phemister techniques revisited. A comparison of intraarticular vs extraarticular fixation methods in the treatment of acute Rockwood type III acromioclavicular dislocations. *Acta Orthop Traumatol Turc.* 2017;51(6):455–458.
32. Walz L, Salzmann GM, Fabbro T, Eichhorn S, Imhoff AB. The anatomic reconstruction of acromioclavicular joint dislocations using 2 TightRope devices: a biomechanical study. *Am J Sports Med.* 2008;36(12):2398–2406.
33. Graupe F, Dauer U, Eyssel M. Late results of surgical treatment of Tossy III acromioclavicular joint separation with the Balsler plate. *Unfallchirurg.* 1995;98(8):422–426.
34. Schindler A, Schmid JP, Heyse C. Temporary fixation with the Balsler hook plate in the treatment of a fresh and complete acromioclavicular joint dislocation. Results of the follow-up of 41 patients. *Unfallchirurg.* 1985;88(12):533–540.
35. McConnell AJ, Yoo DJ, Zdero R, Schemitsch EH, McKee MD. Methods of operative fixation of the acromio-clavicular joint: a biomechanical comparison. *J Orthop Trauma.* 2007;21(4):248–253.
36. Kang S, Min Lee H, Hwa Back I. Acromion fracture after hook plate fixation for distal clavicle injury: a report of 2 cases. *Clin Shoulder Elbow.* 2016;19(3):168–171.
37. Kashii M, Inui H, Yamamoto K. Surgical treatment of distal clavicle fractures using the clavicular hook plate. *Clin Orthop Relat Res.* 2006;447(1):158–164.
38. Renger RJ, Roukema GR, Reurings JC, Raams PM, Font J, Verleisdonk EJ. The clavicle hook plate for Neer type II lateral clavicle fractures. *J Orthop Trauma.* 2009;23(8):570–574.
39. Sun S, Gan M, Sun H, Wu G, Yang H, Zhou F. Does subacromial osteolysis affect shoulder function after clavicle hook plating? *Biomed Res Int.* 2016;2016(1):4085305.
40. Tan HL, Zhao JK, Qian C, Shi Y, Zhou Q. Clinical results of treatment using a clavicular hook plate versus a T-plate in neer type II distal clavicle fractures. *Orthopedics.* 2012;35(8):e1191–e1197.
41. Nadarajah R, Mahaluxmivala J, Amin A, Goodier DW. Clavicular hook-plate: complications of retaining the implant. *Injury.* 2005;36(5):681–683.
42. Muramatsu K, Shigetomi M, Matsunaga T, Murata Y, Taguchi T. Use of the AO hook-plate for treatment of unstable fractures of the distal clavicle. *Arch Orthop Trauma Surg.* 2007;127(3):191–194.
43. Tiren D, van Bommel AJ, Swank DJ, van der Linden FM. Hook plate fixation of acute displaced lateral clavicle fractures: mid-term results and a brief literature overview. *J Orthop Surg Res.* 2012;7(1):2.
44. Ding M, Ni J, Hu J, Song D. Rare complication of clavicular hook plate: clavicle fracture at the medial end of the plate. *J Shoulder Elbow Surg.* 2011;20(7):e18–e20.
45. Spencer Jr EE. Treatment of grade III acromioclavicular joint injuries: a systematic review. *Clin Orthop Relat Res.* 2007;455(1):38–44.
46. Leidel BA, Braunstein V, Kirchoff C, Pilotto S, Mutschler W, Biberthaler P. Consistency of long-term outcome of acute Rockwood grade III acromioclavicular joint separations after K-wire transfixation. *J Trauma.* 2009;66(6):1666–1671.
47. Vrgoc G, Japjec M, Jurina P, et al. Operative treatment of acute acromioclavicular dislocations Rockwood III and V-comparative study between K-wires combined with FiberTape((R)) vs. TightRope System((R)). *Injury.* 2015;46(Suppl 6):S107–S112.
48. Natera-Cisneros L, Sarasquete-Reiriz J, Escola-Benet A, Rodriguez-Miralles J. Acute high-grade acromioclavicular joint injuries treatment: arthroscopic non-rigid coracoclavicular fixation provides better quality of life outcomes than hook plate ORIF. *Orthop Traumatol Surg Res.* 2016;102(1):31–39.
49. Horst K, Dienstknecht T, Andruszkow H, Gradl G, Kobbe P, Pape HC. Radiographic changes in the operative treatment of acute acromioclavicular joint dislocation - tight rope technique vs. K-wire fixation. *Pol J Radiol.* 2013;78(4):15–20.
50. Darabos N, Vlahovic I, Gusic N, Darabos A, Bakota B, Miklic D. Is AC TightRope fixation better than Bosworth screw fixation for minimally invasive operative treatment of Rockwood III AC joint injury? *Injury.* 2015;46(Suppl 6):S113–S118.
51. Li X, Ma R, Bedi A, Dines DM, Altchek DW, Dines JS. Management of acromioclavicular joint injuries. *J Bone Joint Surg Am.* 2014;96(1):73–84.
52. Patzer T, Clauss C, Kuhne CA, et al. Arthroscopically assisted reduction of acute acromioclavicular joint separations: comparison of clinical and radiological results of single versus double TightRope technique. *Unfallchirurg.* 2013;116(5):442–450.
53. Stein T, Muller D, Blank M, et al. Stabilization of acute high-grade acromioclavicular joint separation: a prospective assessment of the clavicular hook plate versus the double double-button suture procedure. *Am J Sports Med.* 2018;46(11):2725–2734.