



Treatment of infected nonunion of the juxta-articular region of the distal tibia

İbrahim Levent ERALP¹, Mehmet KOCAOĞLU², Göksel DİKMEN³, Mohsin E AZAM⁴,
Halil İbrahim BALCI¹, F. Erkal BİLEN²

¹Istanbul University İstanbul Faculty of Medicine, Department of Orthopedics and Traumatology, İstanbul, Turkey

²Istanbul Memorial Hospital, Department of Orthopedics and Traumatology, İstanbul, Turkey

³Acibadem University, Acibadem Maslak Hospital, Department of Orthopedics and Traumatology, İstanbul, Turkey

⁴Memon Medical İnstitute Hospital, Department of Orthopedics and Traumatology, Karachi, Pakistan

Objective: The purpose of this study was to summarize our clinical results with distraction osteogenesis for the treatment of infected tibial nonunion around the ankle joint.

Methods: Between 1994 and 2009, 13 patients with a mean age of 50 years (range: 27–79 years) underwent tibial reconstruction for the treatment of infected nonunion of the distal tibia, with a mean bone loss of 4.8 cm (range: 1–7 cm). Lengthening over an intramedullary nail as a second procedure was used in 2 patients, bifocal compression and distraction technique in 5 cases, compression with Ilizarov external fixator in 5 cases, and Taylor Spatial Frame (TSE, Smith & Nephew, Memphis, TN, USA) in 1 case. At final follow-up, functional and radiographic results were evaluated according to Paley's bone and functional healing criteria.

Results: Mean duration of follow-up was 36 months. Mean external fixation time was 198 days, and mean external fixation index was 29 days/cm. According to Paley's bone healing criteria, there were 10 excellent, 2 good, and 1 poor result(s); additionally, according to Paley's functional healing criteria, there were 5 excellent, 6 good, and 2 fair results. There were 11 problems, 5 obstacles, and 1 sequel according to Paley's classification of complications. There was 1 persisting nonunion, which underwent revision with a retrograde intramedullary nail.

Conclusion: External fixator and/or combined treatment are effective and reliable methods to treat infected nonunion of the distal tibia. Every patient should be evaluated according to their infection level and bony defects for reconstruction.

Keywords: Distal tibia; infection; juxta-articular; nonunion; reconstruction.

Level of Evidence: Level IV, Therapeutic study.

Infected nonunion of the juxta-articular region of the distal tibia is complex and extremely difficult to manage because of coexisting problems such as diffuse osteo-

porosis of small distal bone fragments, deformity, bone loss, soft tissue atrophy, and adjacent joint contracture.^[1] Periarticular distal tibia nonunion around the ankle joint

Correspondence: Göksel Dikmen, MD. Acibadem Maslak Hastanesi, Büyükdere Cad., No: 40, Maslak, 34457 İstanbul, Turkey.

Tel: +90 212 – 304 43 73 e-mail: gdkmen@yahoo.com


Submitted: March 05, 2015 **Accepted:** August 31, 2015

©2016 Turkish Association of Orthopaedics and Traumatology

Available online at
www.aott.org.tr

doi: 10.3944/AOTT.2015.15.0147

QR (Quick Response) Code



presents different treatment challenges from nonunion in the diaphyseal region because of the small size of the distal articular bony fragments. Various treatment options exist for reconstruction of distal tibia nonunion. However, treatment modalities for cases of infection vary widely, with different techniques having been used in small retrospective case series. Internal and external fixation techniques with arthrodesis and preservation of the ankle joint for management of distal infected nonunion around the ankle region have been described. Possible treatment methods include blade plate-screw fixation with autogenous bone grafting, temporary external fixation and plating, acute shortening and lengthening, bone transport with external fixator, and combined technique.

External fixation and distraction osteogenesis are methods that have been documented to improve the outcome of nonunion.^[2] These techniques allow for the regeneration of large deficiencies in bone. To fill the defect, bone transport and shortening-distraction may be used.^[3] Distraction osteogenesis can be achieved by different kinds of external fixations, including unilateral or circular fixators.^[4] Nevertheless, the utilization of external fixators has been associated with many complications. Pin site infection, joint stiffness, deformity, refracture, nonunion, delayed union, soft tissue problems, and mal-alignment have been reported.^[5] In order to reduce these complications, circular external fixator has been used in combination with an intramedullary nail to achieve ankle arthrodesis, bone transport, and/or arrange limb length discrepancy. This method allows for earlier removal of the circular external fixator while the intramedullary nail protects the regenerated bone and the ankle arthrodesis from angulation and displacement.

There are few reports in the literature investigating treatments of infected distal tibia nonunion around the ankle joint. The current retrospective study summarizes our clinical experience with circular external fixator and combined technique (external fixator and intramedullary nail) for the reconstruction of infected distal tibial nonunion.

Patients and methods

Between 1994 and 2009, 13 patients were treated for infected juxta-articular nonunion around the ankle joint, with a mean bone loss of 4.8 cm (range: 1–7 cm). Mean age of the patients was 50 years (range: 27–79 years), and mean number of previous operations was 1.77 (range: 1–4). Demographic data were collected after reviewing the medical records and registry of patients maintained

in our department. All patients were assessed for local skin conditions, shortening, deformity, distal neurovascular status, and joint function. At the time of final follow-up, the functional and radiographic results were evaluated according to the healing criteria of Paley et al. The complications were also evaluated according to the criteria described by Paley.^[7] Paley's system was used to classify nonunion in this study. Accordingly, there were 8 A1, 2 B2, 2 B3, and 1 A2-1 nonunions.^[4] Bone infection was classified according to Cierny-Mader classification. There were 9 IIIB and 4 IVB^[6] chronic infections. Nine patients displayed surgical site infection-related osteomyelitis, and 4 patients had infected open fractures.

The area of resection was determined according to preoperative planning on X-rays and magnetic resonance imaging on T2. Oral and intravenous antibiotics were discontinued 2 weeks before the debridement to obtain an accurate culture of the infecting bacteria, with the exception of patients who had an expanding abscess which required emergency debridement (Figure 2a). Position of internal hardware was determined to plan the necessary surgical procedure for removal. After removal of internal or external devices, dead bone was resected until the point of cortical bleeding, known as the 'Paprika sign.' The bone and surrounding soft tissue were sent as 4 to 5 separate cultures to the microbiology laboratory.

Transverse incision was primarily used for debridement at the distal tibia region; if the soft tissue enveloped was sufficient, the wound was closed with nylon sutures. However, when soft tissue defect was greater than 2 cm, local or free flap application was utilized to obtain adequate coverage for the resected bone bed. After debridement, the leg was splinted or braced. If further bone and tissue resection was needed, additional debridement was planned. After the initial debridement, broad-spectrum antibiotics (gram-positive and -negative bacteria) were given, according to an infectious disease consultant, pending identification of the infecting agent. When the infected nonunion had been cleaned of bleeding tissue by debridement and had received 7–10 days of intravenous antibiotics, reconstruction was scheduled for the distal tibia.

Radical debridement, temporary external fixation, and antibiotic-impregnated cement were used as the first step in 2 cases which had active serious infections with high C-reactive protein values and active purulent discharge. Cement in the form of a chain of beads containing a combination of 2.4 g of teicoplanin or 2 g of vancomycin and 40 g of polymethyl methacrylate powder was applied to the infected sites after resection

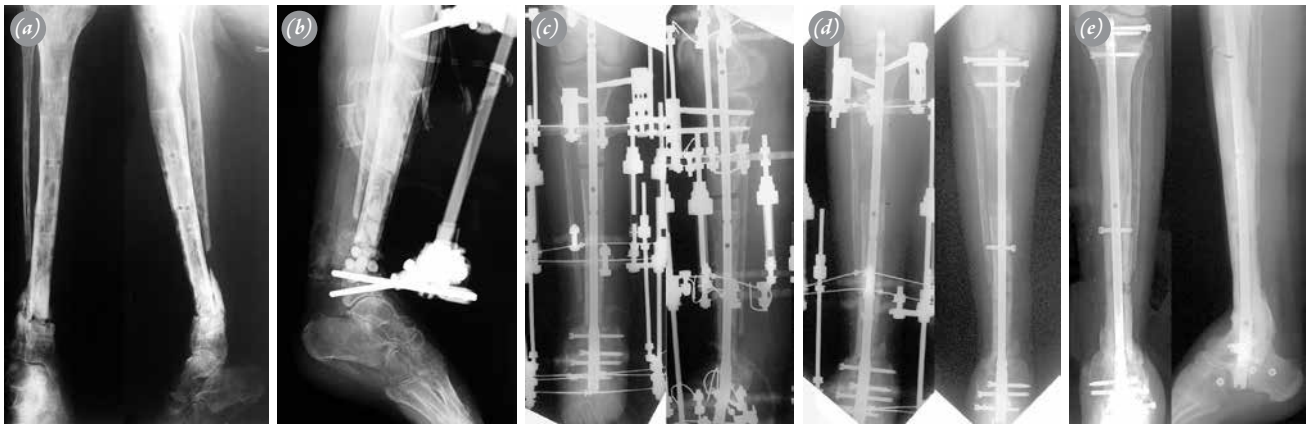


Fig. 1. Case 11, a 28-year-old woman with surgical site infection-related osteomyelitis with a pathological fracture after resection of synovial sarcoma. **(a)** Photograph taken when the patient was first evaluated, showing the pathological fracture and infected nonunion of the distal tibia. **(b)** Radiograph taken after radical debridement and resection of infected bone, followed by insertion of antibiotic beads and a temporary external fixator to create dead space. **(c)** Postoperative anteroposterior radiograph showing the temporary knee fixation for limb length equalization and pantalar arthrodesis, with an intramedullary nail passing through the calcaneus, talus, tibia, and the circular external fixator. **(d)** Plain radiograph taken when the limb length equalization was completed before external fixator removal. Anteroposterior radiograph taken after the nonunion site was docked, the external fixator had been removed, and the locking screws had been inserted at the predrilled holes in the intramedullary nail. **(e)** Anteroposterior and lateral radiograph showing union at the arthrodesis site and the nonunion site.

with monolateral temporary external fixator. Highest-level bone resection was performed in these 2 patients. After the bone bed was prepared for reconstruction, bone transport over an intramedullary nail was used in a second session (Figures 1a–e) to maintain arthrodesis, lengthening, and large segment transfer without alignment problems in a short time period.

Bifocal compression and distraction techniques were utilized in 5 cases (Figures 2a–e), compression with an Ilizarov external fixator was used in 5 cases, and a Taylor Spatial Frame (TSF, Smith & Nephew, Memphis,

TN, USA) was used in 1 case. A free latissimus dorsi myocutaneous flap was required to close the soft tissue defect resulting from infection debridement in 1 patient. The ankle joint was preserved in 8 patients, and arthrodesis was performed in 5 patients. The criteria for joint preservation were good subchondral bone for wire and pin insertion, intact joint cartilage, and no active septic arthritis.

In addition, culture-specific antibiotics were administered for a minimum of 6 weeks, the initial 3 weeks being parenteral. All patients had 1 or more organisms

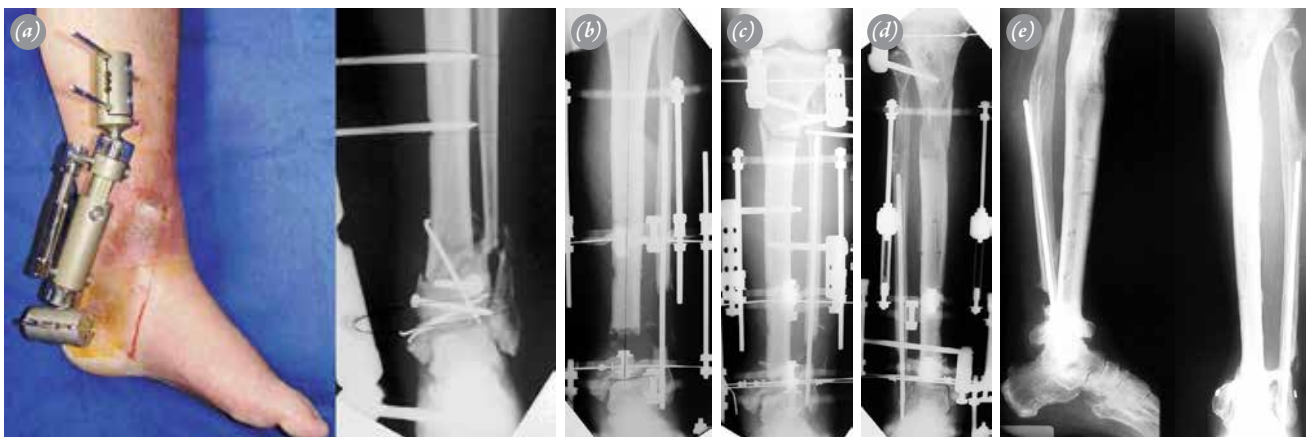


Fig. 2. Case 6, a 53-year-old man with surgical site infection-related osteomyelitis of the distal third of the left tibia. **(a)** Photograph taken when the patient was first evaluated, showing failed monolateral external fixation with a wound over the anteromedial aspect of the left leg. Plain radiograph taken at presentation showing the first operation; the bone had not united. **(b)** Radiograph taken after radical debridement and resection of the infected bone before acute shortening intraoperatively. **(c)** Postoperative anteroposterior radiograph showing the distal compression site and the proximal osteotomy site within the circular external fixator. **(d)** Plain radiograph taken when the proximal lengthening site and distal compression site had united before external fixator removal. **(e)** Anteroposterior and lateral radiographs showing union. [Color figures can be viewed in the online issue, which is available at www.aott.org.tr]

cultured. The 8 patients with staphylococcal infections received 3 weeks of intravenous vancomycin, followed by 3 weeks of PO doxycycline. In 2 patients, *Pseudomonas aeruginosa* and *Escherichia coli* were found; treatment consisted of 3 weeks of intravenous ceftazidime plus levofloxacin, followed by 3 weeks of PO levofloxacin. In 3 patients, coagulase negative staphylococcus was identified and treated with 3 weeks of intravenous vancomycin, followed by PO Bactrim for 3 weeks. The authors of the study received no funding from outside sources.

Results

Results are displayed in Table 1. Mean duration of follow-up was 36 months (range: 16–70 months). Mean external fixation time was 198 days (range: 120–300 days), and mean external fixation index was calculated by number of days divided by lengthening (cm).^[8] The treatment techniques were separated for bone indexes. There were 2 combined technique, 6 bifocal compression and distraction, and 5 monofocal compression patients. One patient who did not achieve union with bifocal compression with TSF was excluded from the bone index calculation. Results are presented as cm defect/frame of time (days) and were 7/300, 2/120, 7/255, and 3/200, producing a bone index of 46 days/cm. There were 2 combined frame over nail patients (7/135, 6/165), with a bone index of 23 days/cm.

According to Paley's bone healing criteria,^[7] an excellent bone result is one with union, no infection, deformity $<7^\circ$, and length discrepancy <2.5 cm in the tibia. A good result was union plus any 2 of the other criteria. A fair result was union plus 1 of the other criteria. A poor result was nonunion or refracture while meeting no other criteria. According to this system, our results included 5 excellent, 6 good, and 2 fair. The functional results were based on the 5 criteria described by Paley: significant limp, equine rigidity of the ankle, soft tissue dystrophy (skin hypersensitivity, insensitivity of the sole, or decubitus), pain, and inactivity (unemployment because of the leg injury or inability to return to daily activities because of the leg injury). An excellent result was an active individual with none of the other 4 criteria, a good result was an active individual with 1 or 2 of the other 4 criteria, and a fair result was an active individual with 3 or 4 of the other criteria or an amputation. An inactive individual was considered a poor result regardless of the other criteria.^[7] Based on the functional criteria, there were 10 excellent, 2 good, and 1 poor result(s). Union was achieved in 12 patients, while 1 patient had nonunion. American Orthopaedic Foot and Ankle Soci-

ety (AOFAS) scores ranged from 40 to 92, with a mean of 68.8. There was no difference in mean AOFAS scores between patients with arthrodesis (mean: 70.8) and patients with joint preservation (mean: 72).

There were 11 complications that had to be resolved in the outpatient clinic. There were 5 obstacles that required additional operative intervention for resolution. Complications were grouped as minor, major without residual sequelae, and major with residual sequelae. Minor complications generally required nonoperative treatment or a minor operative procedure that did not impact the final result.^[8] The complications involved 7 grade 2 pin tract infections, 1 transient case of knee joint stiffness, and 3 cases of ankle joint stiffness. The obstacles involved 2 grade 3 pin tract infections and 3 equine deformities. Pin tract infections were graded according to Paley.^[9] A complication was observed in 1 case, which was reconstructed with the TSF system and underwent revision with a retrograde intramedullary nail because of persisting nonunion after TSF. Kirschner wire breakages occurred at the distal part of the fixator, which were replaced. One patient received a free latissimus dorsi flap, 2 patients received local fasciocutaneous flaps for coverage, and 5 patients required docking-site bone grafting.

Discussion

Reconstruction after distal tibial juxta-articular bone loss remains a therapeutic challenge for orthopedic surgeons. Achievement of a stable plantigrade foot without limb length discrepancy remains the ultimate goal.^[10]

Nonunion of juxta-articular fractures is not commonly encountered, which is probably due to the good vascularity of this area rendered by a rich network of metaphyseal vessels and to the rapid healing capability of periarticular cancellous bone.^[11] However, if the internal fixation of a comminuted closed fracture results in infection or if there is substantial periosteal stripping, soft tissue necrosis, or bone loss due to a high-energy injury, nonunion may occur.^[12] Management of such nonunions is extremely difficult because of several coexisting problems, including medical comorbidities and local factors, such as a poor soft tissue envelope and small osteoporotic fragments, which may limit fixation options and compromise fixation stability.^[13]

Different methods that have been used include external fixation with monolateral or circular fixators, as well as a combined technique in which external fixation is combined with an intramedullary nail. The use of external fixation combined with an intramedullary nail has been advocated in the literature for defects in long

Table 1. Patient demographic and outcome data.

Case	Gender	Diagnosis	Fixation Type	Follow-up (month)	Bone resection length (cm)	Preop LLD	Lengthening	Postop LLD	Cierny-Mader type	Paley long bone nonunion classification	External fixator index (day/cm)	External fixation time (days)	Final bone status	Final functional status	Complications
1	M, 43	SSI-related OM	Ilizarov (monofocal compression with angular correction)	20	2	1	0	3	IIIB	A1	30	270	Union	Excellent	Minor pin tract infection
2	M, 46	Open-fx-infected nonunion	Ilizarov (bifocal compression distraction)	39	None	2	2	0	IIIB	A1	30	150	Union	Good	Minor and major pin-tract infection, equinus deformity
3	M, 63	SSI-related OM	Ilizarov (monofocal compression, arthrodesis)	20	None	1	0	2	IIIB	A1	26.2	210	Union	Good	Minor and major pin tract infection, ankle movement stiffness
4	M, 35	SSI-related OM	Ilizarov (monofocal compression)	36	None	2	0	3	III	A1	26.2	210	Union	Good	Minor pin tract infection, equinus deformity, ankle movement stiffness
5	M, 71	Open-fx-infected nonunion	Combined technique (ankle arthrodesis)	63	7	0	7	0	IVB	B2	19.2	135	Union	Good	Minor pin tract infection, equinus deformity, ankle movement stiffness
6	M, 53	SSI-related OM	Ilizarov (bifocal compression distraction)	18	3	4	7	0	IVB	A1	30	300	Union	Excellent	None
7	M, 66	SSI-related OM	Ilizarov (monofocal compression)	16	2*	0	0	0	IIIB	A2-1	30	120	Union	Good	None
8	F, 79	SSI-related OM	Ilizarov (bifocal compression distraction)	36	3	1	5	1	IVB	B2	36.2	255	Union	Good	None
9	M, 41	Open-fx-infected nonunion	Ilizarov (bifocal compression distraction)	24	3	2	3	2	IIIB	B3	33.3	200	Union	Fair	Minor pin tract infection, malalignment >5°
10	F, 38	SSI related OM	Taylor spatial frame (ankle arthrodesis)	51	2	2	0	4	IIIB	B3	27	270	Nonunion	Fair	Revision ankle retrograde IMN
11	F, 28	SSI related OM	Combined technique (pantalar arthrodesis)	70	7	0	7	0	IVB	A1	27.5	165	Union	Excellent	None
12	F, 33	Open-fx-infected nonunion	Ilizarov (bifocal compression distraction)	18	None	1	1	0	IIIB	A1	30	180	Union	Excellent	Minor pin tract infection
13	M, 66	SSI-related OM	Ilizarov (monofocal compression, arthrodesis)	60	None	1	0	1	III	A1	30	120	Union	Excellent	None

* The opposite leg was amputated due to traffic accident.
 SSI-related OM: Surgery site-related osteomyelitis; Preop: Preoperative; Postop: Postoperative; LLD: Limb length discrepancy; IMN: Intramedullary nail.

Table 2. Review of the literature.

Study	Patients infected	Results	Frame Time (Mount)	Complications	Defect	Technique
Green and Roesler 1987 ^[23]	11	2 union, 4 arthrodesis	8–12	2 chronic infection, 2 nonunion, 1 amputation	None	Ex. fixator (Hoffman)
Zalavras et al. 2004 ^[19]	6	4 union, 4 arthrodesis	8	2 nonunion, 1 LLD (1.6 cm)	4.2 cm	Ex. fixator
Stasikiles et al. 1993 ^[20]	6	6 arthrodesis, 1 LLD	8	2 deformity 15 deformation transport, 1 regenerated fracture	3.8 cm	Ex. fixator (Ilizarov)
Kabata et al. 2005 ^[1]	2	2 union	7.3	None	2.9 cm	Ex. fixator
Present study	13	12 union 5 arthrodesis	6.6	1 Nonunion	4.6 cm	Ex. fixator, combined

LLD: Limb length discrepancy; Ex: External.

bones due to tumors, infections, and nonunions.^[14] The Masquelet technique can be used for bone defect due to infection and entails the insertion of a cement spacer loaded with or without antibiotics. Generally preferred for posttraumatic defects, this approach maintains the space of reconstruction or bone transport.^[15]

When using the classical Ilizarov technique, many strategies for osteogenesis can be used, such as compression, compression distraction (accordion), and segment transport with 1 or more segments (bifocal, trifocal, etc.). The advantage of the Ilizarov frame is its three-dimensional nature, which renders the technique extremely versatile and capable of accommodating complex abnormalities of the tibia, ankle, and foot.^[16]

Apart from external fixator-only techniques, many cases in the literature have been treated with the addition of an intramedullary device, known as the combined technique. Paley et al. used the combined technique for femur lengthening, Kocaoglu et al. used the same technique with the tibia for osteomyelitis and nonunions, and Tsuchiya used it for defects following tumor resection.^[5,13,17] This technique has many advantages, including a significant reduction in external fixator time, maintenance of alignment during segment transport, and a reduction in complications, such as refracture and plastic deformation. Additionally, it also allows for early weight-bearing and rehabilitation.

Upon review of the literature, we found different case series describing juxta-articular nonunions around the ankle (Table 2). Green and Roesler used Hoffman external fixators to treat 11 infected cases of pilon fracture nonunions. This technique uses the Hoffman external fixator with transfixation pins through the tibia, hind foot, and forefoot to achieve rigid fixation, which prevents the patient from walking when the fixator is in

place. The external fixator was used for 8–12 months. During this period, there were 2 chronic infections and 2 nonunions.^[18] The advantage that we observed when using circular fixators and the combined technique is the ability for patients to achieve earlier mobilization and rehabilitation; furthermore, early fixator removal is possible with the combined technique. In Zalavras et al.'s series, the limb salvage protocol included 3 stages: radical debridement and stabilization of the ankle with a bridging external fixator, soft tissue coverage with free muscle flaps, and ankle fusion using an iliac crest bone graft to fill defects measuring 4.2 cm on average. At a mean follow-up of 5.5 years, infection-free limb salvage was accomplished in all patients.^[19] A similar strategy was used in the present study for infection eradication, but segment transport was used instead of iliac crest bone graft. Stasikiles et al. treated 6 patients with chronic osteomyelitis of the tibia complicating a pilon fracture using the Ilizarov technique. At a mean follow-up of 30 months, infection-free solid fusion was achieved in all patients, but 8 additional procedures were needed, and 1 patient sustained a fracture during the regenerative period.^[20] In our series, the mean follow-up period was 36.2 months. Union was achieved in 12 of the 13 patients; in 1 patient, union was achieved after reoperation by the insertion of a retrograde intramedullary nail. Kabata et al. successfully treated 2 patients with external fixation, only performing shortening and distraction in distal tibia osteomyelitis following internal fixation for open fracture.^[1] We treated 5 patients with a similar technique. Ciorny et al. treated infected nonunions of ankle fractures with aggressive debridement, excising all necrotic bone (as the essential step of the treatment), followed by half-pin external fixation. The authors treated 34 ankle and distal tibia fracture non-

unions but did not specifically classify infected juxta-articular nonunions.^[21] This approach proved to be an effective technique in eradicating infection.

In the present study, ankle arthrodesis was performed in 5 cases. We believe arthrodesis to be advantageous in some cases, depending on the patient's age, body weight, and desired level of activity. In the presence of poor metaphyseal bone stock, arthrodesis offers the potential advantages of being a stable, durable, and predictable reconstruction that enables unrestricted activity.^[22]

Our study had several limitations. First, it was a retrospective evaluation of prospectively monitored patients, which means that there was a possibility of selection bias. Second, treatment techniques were not uniform. Third, the follow-up period was only mid- to long-term. However, juxta-articular distal tibia osteomyelitis remains a complex and technically demanding problem that requires an aggressive approach in treatment and experience to achieve good and reproducible functional results.

Conclusion

Juxta-articular fractures may be associated with subsequent nonunion and infection. The initial sequence of treatment for infected nonunions is extensive debridement followed by removal of hardware. When external fixation is used for definitive reconstruction, bone grafting of the nonunion or docking site is required in cases with delayed union. In cases in which preservation of the plafond is not possible in juxta-articular reconstructions, arthrodesis of the ankle and subtalar joint may be necessary for reconstruction. In our case series, the external fixation technique successfully addressed all complications in distal tibial osteomyelitis, with a favorable functional outcome in all cases.

Conflicts of Interest: No conflicts declared.

References

- Kabata T, Tsuchiya H, Sakurakichi K, Yamashiro T, Watanabe K, Tomita K. Reconstruction with distraction osteogenesis for juxta-articular nonunions with bone loss. *J Trauma* 2005;58:1213–22. [CrossRef](#)
- Lonner JH, Koval KJ, Golyakhovsky V, Frankel VH. Post-traumatic nonunion of the distal tibial metaphysis. Treatment using the Ilizarov circular external fixator. *Am J Orthop (Belle Mead NJ)* 1995;Suppl:16–21.
- Tsuchiya H, Tomita K, Minematsu K, Mori Y, Asada N, Kitano S. Limb salvage using distraction osteogenesis. A classification of the technique. *J Bone Joint Surg Br* 1997;79:403–11. [CrossRef](#)
- Paley D, Catagni MA, Argnani F, Villa A, Benedetti GB, Cattaneo R. Ilizarov treatment of tibial nonunions with bone loss. *Clin Orthop Relat Res* 1989;241:146–65. [CrossRef](#)
- Eralp L, Kocaoglu M. Distal tibial reconstruction with use of a circular external fixator and an intramedullary nail. Surgical technique. *J Bone Joint Surg Am* 2008;90 Suppl 2 Pt 2:181–94. [CrossRef](#)
- Cierny G 3rd, Mader JT, Penninck JJ. A clinical staging system for adult osteomyelitis. *Clin Orthop Relat Res* 2003;414:7–24. [CrossRef](#)
- Paley D, Maar DC. Ilizarov bone transport treatment for tibial defects. *J Orthop Trauma* 2000;14:76–85. [CrossRef](#)
- Kocaoglu M, Eralp L, Rashid HU, Sen C, Bilsel K. Reconstruction of segmental bone defects due to chronic osteomyelitis with use of an external fixator and an intramedullary nail. *J Bone Joint Surg Am* 2006;88:2137–45. [CrossRef](#)
- Paley D. Problems, obstacles, and complications of limb lengthening by the Ilizarov technique. *Clin Orthop Relat Res* 1990;250:81–104. [CrossRef](#)
- Eralp L, Kocaoglu M, Yusof NM, Bulbul M. Distal tibial reconstruction with use of a circular external fixator and an intramedullary nail. The combined technique. *J Bone Joint Surg Am* 2007;89:2218–24. [CrossRef](#)
- Rhineland FW. Tibial blood supply in relation to fracture healing. *Clin Orthop Relat Res* 1974;105:34–81.
- Mosheiff R, Safran O, Segal D, Liebergall M. The unreamed tibial nail in the treatment of distal metaphyseal fractures. *Injury* 1999;30:83–90. [CrossRef](#)
- Mandt PR, Gershuni DH. Treatment of nonunion of fractures in the epiphyseal-metaphyseal region of long bones. *J Orthop Trauma* 1987;1:141–51. [CrossRef](#)
- Paley D, Herzenberg JE, Paremian G, Bhave A. Femoral lengthening over an intramedullary nail. A matched-case comparison with Ilizarov femoral lengthening. *J Bone Joint Surg Am* 1997;79:1464–80.
- Giannoudis PV, Faour O, Goff T, Kanakaris N, Dimitriou R. Masquelet technique for the treatment of bone defects: tips-tricks and future directions. *Injury* 2011;42:591–8.
- Paley D, Lamm BM, Katsenis D, Bhave A, Herzenberg JE. Treatment of malunion and nonunion at the site of an ankle fusion with the Ilizarov apparatus. Surgical technique. *J Bone Joint Surg Am* 2006;88 Suppl 1 Pt 1:119–34.
- Tsuchiya H, Tomita K, Shinokawa Y, Minematsu K, Katsuo S, Taki J. The Ilizarov method in the management of giant-cell tumours of the proximal tibia. *J Bone Joint Surg Br* 1996;78:264–9.
- Hutson JJ Jr. Salvage of pilon fracture nonunion and infection with circular tensioned wire fixation. *Foot Ankle Clin* 2008;13:29–68. [CrossRef](#)
- Zalavras CG, Patzakis MJ, Thordarson DB, Shah S, Sherman R, Holtom P. Infected fractures of the distal tibial metaphysis and plafond: achievement of limb salvage with free

- muscle flaps, bone grafting, and ankle fusion. *Clin Orthop Relat Res* 2004;427:57–62. [CrossRef](#)
20. Stasikelis PJ, Calhoun JH, Ledbetter BR, Anger DM, Mader JT. Treatment of infected pilon nonunions with small pin fixators. *Foot Ankle* 1993;14:373–9. [CrossRef](#)
21. Cierny G 3rd, Cook WG, Mader JT. Ankle arthrodesis in the presence of ongoing sepsis. Indications, methods, and results. *Orthop Clin North Am* 1989;20:709–21.
22. Vidyadhara S, Rao SK. A novel approach to juxta-articular aggressive and recurrent giant cell tumours: resection arthrodesis using bone transport over an intramedullary nail. *Int Orthop* 2007;31:179–84. [CrossRef](#)
23. Green SA, Roesler S. Salvage of the infected pilon fracture. *Techniques in Orthopedics* 1987;2:37–41. [CrossRef](#)