


Contents lists available at [ScienceDirect](https://www.elsevier.com/locate/aott)

## Acta Orthopaedica et Traumatologica Turcica

journal homepage: <https://www.elsevier.com/locate/aott>

## Functional and radiological results of percutaneous K-wire aided Métaizeau technique in the treatment of displaced radial neck fractures in children

Nazan Çevik, Gökhan Cansabuncu\*, Yavuz Akalın, Ali Otuzbir, Alpaslan Öztürk, Yüksel Özkan

Bursa High Specialty Research and Training Hospital, Department of Orthopedics and Traumatology, Yildirim, Bursa, Turkey



## ARTICLE INFO

## Article history:

Received 7 April 2017

Received in revised form

26 July 2018

Accepted 30 July 2018

Available online 11 September 2018

## Keywords:

Métaizeau Technique

Pediatric fractures

Radial neck fracture

Percutaneous reduction

Treatment

## ABSTRACT

**Objectives:** The aim of the present study was to determine the radiological and functional results and the efficiency of paediatric radial neck fracture fixation following reduction with the Métaizeau technique together with percutaneous K-wire applied under fluoroscopy to ensure minimum soft tissue damage.

**Methods:** The study included 20 patients with Judet Type 3, Type 4a and Type 4b fractures operated on with the Métaizeau technique aided by percutaneous K-wire between 2007 and 2014. The mean age of the patients was 9.75 years (range, 4–13 years). Mean preoperative angulation was measured as 52.4° (range, 35°–85°). The average postoperative follow-up time was 34.65 months (range, 13–84) months. Postoperative radiological evaluations were made according to the Ursei classification and functional assessment with the Tibone – Stoltz classification system.

**Results:** Radiologically, the difference between preoperative and postoperative radius head angulation was found statistically significant ( $p=0.001$ ). In the clinical assessment of injured and uninjured arms, there was no statistically significant difference between flexion-extension ( $p=0.330$ ) and supination-pronation range of motion ( $p=0.330$ ) and carrying angles ( $p=0.094$ ). According to the radiological Ursei evaluation, 17 (85%) patients were in perfect condition and 3 (15%) were good. In the classification of Tibone – Stoltz, 16 (80%) patients were evaluated as perfect, 3 (15%) as good and 1 (5%) as fair.

**Conclusion:** From the results of this study and related literature, the use of the Métaizeau technique in displaced radial neck fractures requiring surgical treatment in children can be recommended since it creates minimum damage to the soft tissue, is easy to apply and the results are satisfactory.

**Level of evidence:** Level IV, therapeutic study.

© 2018 Turkish Association of Orthopaedics and Traumatology. Publishing services by Elsevier B.V. This is an open access article under the CC BY-NC-ND license (<http://creativecommons.org/licenses/by-nc-nd/4.0/>).

## Introduction

Radial neck fractures account for more than 1% of all fractures in childhood.<sup>1</sup> Since radial head ossification does not occur prior to age 5 years, these fractures are frequently seen in children aged 4–14 years.<sup>2</sup> This injury is often the result of falling onto an outstretched open hand. The capitellum of the extended elbow exerts a

strong force on the proximal radius and this force may result in a fracture along the radius together with the fall. As a result of valgus stress, accompanying injuries may occur such as ulnar epicondylar avulsion fractures, rupture of the ulnar capsule and collateral ligament, olecranon and ulna fractures.<sup>3</sup> Radial neck fractures can be treated with methods such as closed reduction and casting, closed reduction intramedullary fixation, percutaneous reduction and fixation, intramedullary reduction and fixation and open reduction.<sup>4</sup> Most radial neck fractures with no displacement or minor angulation (Judet Type 1 or 2) are treated with conservative methods,<sup>5</sup> whereas fractures with serious displacement and angulation (Judet Type 3 and 4) require surgery.<sup>3,4,6–10</sup> Although the decision of treatment method to be used is strongly determined by the amount of angulation, the patient's age, amount of

\* Corresponding author. Bursa High Research and Training Hospital, Department of Orthopedics and Traumatology, Bursa, Turkey. Tel.: +905333466965.

E-mail address: [cansabuncu@gmail.com](mailto:cansabuncu@gmail.com) (G. Cansabuncu).

Peer review under responsibility of Turkish Association of Orthopaedics and Traumatology.

**Table 1**  
Judet classification.

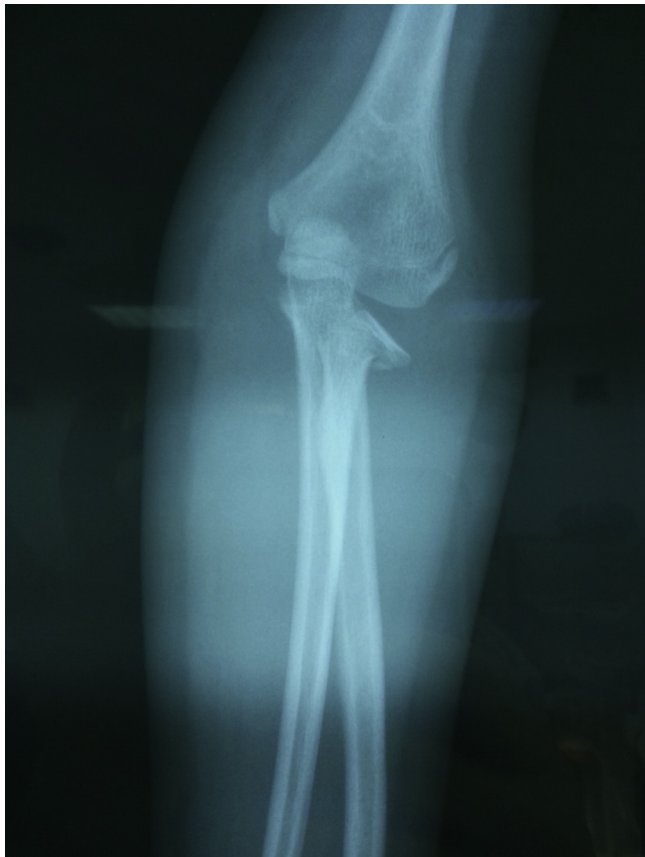Type 1	Fractures with no displacement or displaced without angulation
Type 2	Angulations under 30°
Type 3	Angulations between 30° and 60°
Type 4A	Angulations between 60° and 80°
Type 4B	Angulations over 80°

translation, and the time since the injury are also important factors when designing the treatment plan.<sup>11</sup> Following any of the treatment methods, complications such as pain in the joint, limitation of motion, cubitus valgus, radioulnar synostosis, heterotopic ossification, enlargement of the radial head, premature fusion of the physal plate, avascular necrosis, malunion and non-union may be seen in pediatric radial neck fractures.

The aim of this retrospective study was to evaluate the efficiency and determine the radiological and functional results of reduction followed by fixation using percutaneous K-wire with the Métaizeau technique under fluoroscopy guidance to create minimum soft tissue damage in children treated surgically for a radial neck fracture.

### Material and methods

A retrospective evaluation was made of patients diagnosed with radial neck fractures in the Emergency Department and hospitalized for surgical treatment between June 2007 and September 2014. Patients who had elbow surgery on the same extremity for any reason or those with a history of elbow fracture, those applied with open surgical treatment for radial neck fractures and patients

**Fig. 1.** Preoperative anteroposterior radiograph.**Table 2**  
Demographic data of patients.

Mean Age	9.75 (4–13) years	
Mean follow up	34.65 (13–84) months	
Mean preoperative angulation	52.4° (35°–85°)	
	n	(%)
Gender		
Boys	16	80
Girls	4	20
Judet Type		
3	14	70
4 A	5	25
4 B	1	5
Associated elbow injury		
Yes	4	20
No	16	80

with a follow-up period shorter than one year were excluded from the study.

The fractures were evaluated according to the classification system developed by Judet et al,<sup>12</sup> which was later modified by Métaizeau et al<sup>13,14</sup> (Table 1).

Patients with angulations of >30° underwent surgical treatment Fig. 1. The study included 20 pediatric patients, comprising 16 males and 4 females, with Type 3, Type 4a and Type 4b fractures according to the Judet classification and who were treated with the Métaizeau technique aided by percutaneous K-wire. The mean age of the patients was 9.75 years (range, 4–13 years) and mean follow-up was 34.6 months (range, 13–84 months). The fractures were classified as Judet Type 3 in 14 cases, Type 4a in 5 and Type 4b in 1. Associated injuries were determined in 4 patients; 1 patient with an ulna shaft fracture and 3 with olecranon fractures. The time from trauma to surgery was mean 1.35 days (range, 1–3 days). The demographic data of the patients are presented in Table 2. Postoperative radiological evaluations were made in accordance with the Ursei classification<sup>15</sup> and functional evaluation was made using the Tibone – Stoltz classification<sup>16</sup> (Tables 3 and 4).

### Surgical technique

The surgical operation was carried out under general anesthesia. A 2 cm vertical skin incision was made under fluoroscopy guidance at a site 1–2 cm proximal and radial to the distal radius epiphyseal line. The cortex was reached by avoiding the sensory branch of the radial nerve. The lateral cortex was drilled with a 3.2 mm drill. K-wire of 1.5 mm–2.0 mm diameter was selected according to the patient's age and the width of the intramedullary canal. In all patients the blunt tip of the K-wire was curved to approximately 30° and was then advanced through the radius head from the hole opened on the distal radius under fluoroscopic guidance. Then, a 0.5 cm skin incision was made on the posterolateral of the proximal forearm and under fluoroscopy, a 1.8 mm or 2.0 mm K-wire was inserted percutaneously around the fracture line to treat the radial head angulation. Displaced radial head reduction was applied with the help of the percutaneous K-wire. The fracture line was distracted by moving the intramedullary-advanced K-wire more

**Table 3**  
Ursei radiological evaluation classification.

Excellent	Anatomic reduction achieved
Good	Translation or angulation under 20°
Acceptable	Angulation between 20° and 40°
Poor	Angulation over 40°

**Table 4**  
Tibone ve Stoltz functional evaluation classification.

	Pain	Deformity	ROM
Excellent	None	None	Complete
Good	Occasional	Carrying angle increased less than 10°	Limited; under 20°
Fair	Occasional	Carrying angle increased more than 10°	Limited; over 20°
Poor	Radial head excision required for the treatment of pain or limitation of motion in joint		

proximal. Full reduction was achieved by rotating the curved K-wire tip 180° Fig. 2. Postoperatively, whole arm was protected with a plaster cast for 3 weeks. After removal the cast a home exercise program was started. The intramedullary wire was removed after clinical and radiographic consolidation of the fracture that takes place in approximately 6 weeks Fig. 3.

#### Statistical analysis

Statistical analysis was performed using SPSS software (IBM, Armonk, New York, USA). We also performed univariate and multivariate analyses.

#### Results

Of the 20 patients, 16 (80%) were male and 4 (20%) were female. Preoperative mean angulation was measured as 52.4° (range, 35°–85°). The mean age of the patients was 9.75 years (range, 4–13 years). The mean postoperative follow-up time was 34.65 months (range, 13–84 months). While the main injury mechanism in all cases was a fall onto the open hand, 5 patients had fallen from height. Isolated radial neck fracture was determined in 16 (80%) patients and 4 (20%) patients had associated injuries; 3 olecranon fractures and 1 ulna shaft fracture. Of the patients with olecranon fractures, 2 were treated with the tension band technique and the other patient with no displacement was followed conservatively.

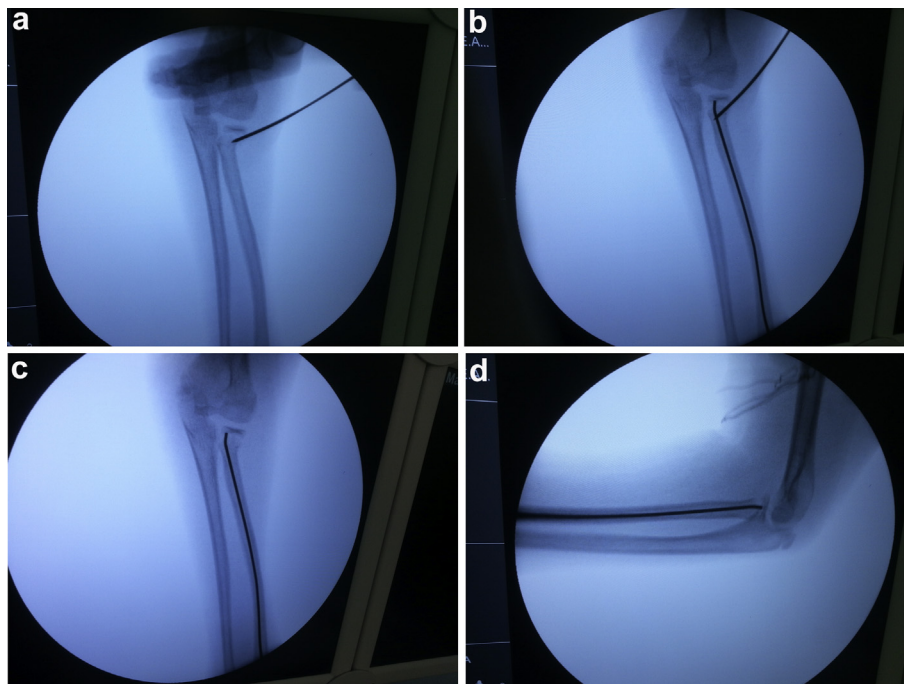
The patient with ulna shaft fracture was applied with intramedullary fixation following closed reduction.

The average time from trauma to operation was 1.35 days (range, 1–3 days). The K-wires were removed at mean 10 weeks postoperatively. According to the Ursei evaluation criteria, 17 (85%) patients were evaluated as perfect and 3 (15%) as good radiologically. According to the Tibone – Stoltz classification system, which assessed clinical and functional results, 16 (80%) patients were evaluated as perfect, 3 (15%) as good and 1 (5%) as fair (Table 5). Radiologically, the difference between preoperative and postoperative radius head angulation was found statistically significant ( $p < 0.001$ ). In the clinical assessment of injured and uninjured arms we measured the elbow range of motions and carrying angles. we preferred radiographic measurement of carrying angle that is the degree between long axis of humerus and ulna on anteroposterior plain radiographs. There was no statistically significant difference between flexion-extension ( $p = 0.330$ ) and supination-pronation range of motion ( $p = 0.330$ ) and carrying angles ( $p = 0.094$ ) (Table 6).

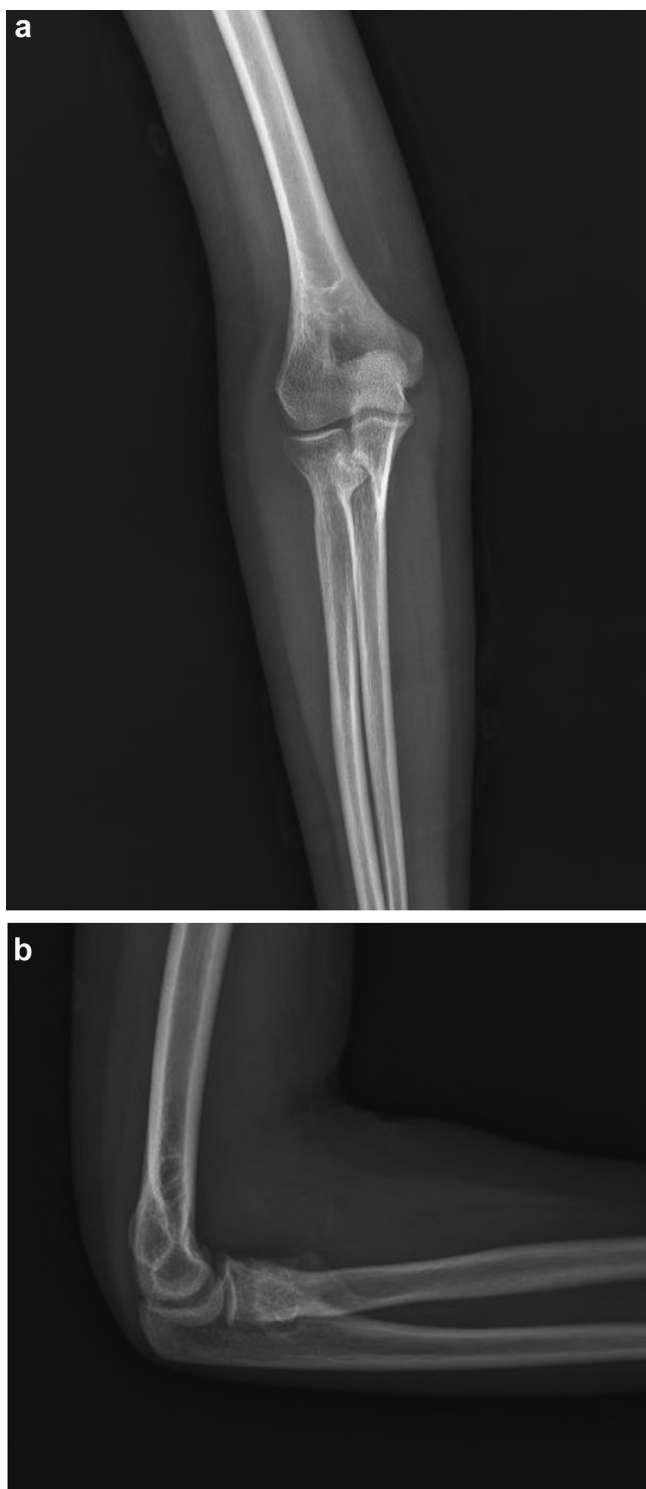
In the postoperative follow-up period, 2 patients were observed to have limitation of motion of 15°, 6 patients had premature fusion of the physeal plate, 1 had avascular necrosis of radial head (Fig. 4), 2 had radial head enlargement and 2 had heterotopic ossification (Fig. 5). None of the patients had synostosis, neurovascular complications or tendon complications due to K-wire irritation or infections.

#### Discussion

Despite the low incidence rates, pediatric radial neck fractures may lead to undesirable results and limitation in elbow movements if undertreated or mistreated. The treatment of radial neck fractures in this age group continues to be a controversial topic. Although the most significant indicator when planning the treatment is the amount of radial neck angulation, the patient's age and the time since the injury also influence the treatment technique to



**Fig. 2.** a) Correction of radial neck fracture using percutaneous K-wire, b-c) Fracture fixation with intramedullary K-wire, d) Intraoperative fluoroscopic lateral view.



**Fig. 3.** a) The postoperative 26 month roentgenography of 12 year-old boy patient shows good alignment of elbow joint and healed fracture of radial neck, b) Postoperative lateral radiograph.

be used<sup>3</sup>. Radial neck fractures may be treated using methods such as closed reduction and casting, closed reduction intramedullary fixation, percutaneous reduction and fixation, intramedullary reduction and fixation and open reduction<sup>4</sup>. While many radial neck fractures with no displacement or little angulation (Judet Type 1 or 2) are treated with conservative methods,<sup>5</sup> fractures with

severe displacement and angulation (Judet Type 3 and 4) are treated surgically through different methods.<sup>3,4,6–10</sup> Although the treatment criteria are controversial, it has been shown that fractures with angulation of  $>60^\circ$  or displacement of  $>3$  mm generally cause unpleasant results if not reduced and that fractures of  $<30^\circ$  of angulation may be safely followed up conservatively.<sup>17</sup> Despite consensus on this point, several studies have reported varying results concerning the treatment protocol.

In a series of 42 patients with advanced deformity ( $60^\circ$ – $90^\circ$ ) Steinber et al<sup>18</sup> stated that 28 patients were treated with closed reduction and plaster fixations and that the initial acceptable reduction criteria were lost in 22 of these patients and thus they required open reduction.

The amount of angulation is the primary criterion in the decision to apply conservative treatment or surgical treatment with any other method. However, the patient's age is also important when defining the treatment indication. Métaizeau et al<sup>13</sup> reported that  $20^\circ$ – $30^\circ$  of angulation in young children may be remodeled in time, but even  $10^\circ$ – $15^\circ$  of angulation in children over 12 years old could not be remodeled. Similarly, Bernstein et al<sup>19</sup> reported that remodeling is possible in angulations of  $60^\circ$  in children up to 6 years of age, but angulations  $>30^\circ$  cannot be corrected in children older than 12 years.

Patients who presented at our hospital with angulation of  $<30^\circ$  in the radial neck were followed up with closed manipulation and a long arm splint. Patients with angulations of  $>30^\circ$  underwent surgical treatment. In the patient group as a whole, the mean preoperative angulation was measured as  $52.4^\circ$  (range,  $35^\circ$ – $85^\circ$ ) and all were treated with intramedullary reduction aided by percutaneous K-wire.

In patients with a high degree of angulation, adequate reduction was achieved with K-wire-aided closed reduction and the radiological evaluations showed excellent results for 17 (85%) patients and good results for 3 (15%). In the clinical evaluations, 16 (80%) patients were evaluated as excellent, 3 (15%) as good and 1 as (5%) fair.

In literature, D'Souza et al<sup>5</sup> recorded excellent and good results for 99% of their patients who were treated with closed or percutaneous reduction. Likewise, in another study, 94% good results were obtained in patients treated with percutaneous reduction and this technique was concluded to be good for many fractures.<sup>20</sup> However, Berstein et al<sup>19</sup> observed that although adequate postoperative reduction had been achieved in patients treated with open reduction and K-wire fixation, the delayed functional results were poor. Schmittenebecher et al<sup>21</sup> reported that worse results were obtained in open reduction applications compared with closed reduction, independent of the fixation method.

Although open reduction internal fixation allows full anatomic reduction, many studies have found that complication rates are higher in comparison with percutaneous reduction, elbow stiffness occurs more frequently and therefore functional results are affected negatively.<sup>13,19,20</sup> For these reasons, open reduction was not used in the surgical operations of this study.

The results of open reduction are often associated with radial head avascular necrosis, premature fusion of the physal plate, enlargement of the radial head and heterotopic ossification, although such complications may be seen as a result of disruption to the blood supply in the radial head during trauma.<sup>14,18,19,21</sup> Nevertheless, avascular necrosis, radioulnar synostosis, infection, non-union, articular surface injury and limitations in range of motion can also be assessed as complications associated with treatment.<sup>17</sup>

Since closed reduction and intramedullary fixation was first suggested by Métaizeau<sup>14</sup> in 1980, it has been frequently and safely used in the treatment of pediatric radial neck fractures<sup>6,9,13,21–25</sup> In



**Table 5**  
Preoperative and postoperative data of the patients.

	Gender	Age	Type Judet/degree	Mechanism	Associated elbow injury	Timing of Surgery (day)	Follow up (month)	Limitation Of ROM	Valgus	HO	Radial Head Enlargement	AVN	Premature fusion of epiphyseal plate	Clinical evaluation	Radiological evaluation
1	B	10	3/35°	Fall	None	1	84	None	0	–	–	–	–	Excellent	Excellent
2	B	12	3/40°	Fall	None	1	59	15 Degree	6	–	–	–	+	Good	Excellent
3	B	12	3/44°	Fall	None	1	30	None	0	+	–	–	–	Excellent	Excellent
4	B	11	3/36°	Fall	None	2	31	None	0	–	–	–	–	Excellent	Excellent
5	B	4	4B/85°	Fall	None	1	34	None	10	–	–	+	+	Fair	Good
6	B	13	3/54°	Fall	None	1	24	None	0	–	–	–	–	Excellent	Excellent
7	B	14	3/40°	Fall	None	1	32	None	0	–	–	–	–	Excellent	Excellent
8	B	8	4A/76°	Fall from height	Ulna Fracture	2	33	None	0	–	–	–	–	Excellent	Excellent
9	G	7	4A/72°	Fall	Olecranon Fracture	1	37	None	0	–	–	–	+	Excellent	Excellent
10	G	10	3/52°	Fall	None	2	13	15 Degree	0	+	–	–	–	Good	Excellent
11	B	12	3/45°	Fall	None	1	49	None	0	–	–	–	–	Excellent	Excellent
12	G	6	4A/78°	Fall from height	Olecranon Fracture	3	24	None	6	+	+	–	–	Good	Good
13	B	11	3/36°	Fall from Height	Olecranon Fracture	1	38	None	0	–	–	–	+	Excellent	Excellent
14	G	7	3/45°	Fall	None	1	34	None	0	–	–	–	–	Excellent	Excellent
15	B	7	3/38°	Fall From Height	None	2	39	None	0	–	–	–	–	Excellent	Excellent
16	B	9	4A/72°	Fall	None	1	21	None	0	–	+	–	+	Excellent	Good
17	B	12	3/45°	Fall	None	1	26	None	0	–	–	–	–	Excellent	Excellent
18	B	8	4A/70°	Fall from Height	None	1	20	None	0	–	–	–	+	Excellent	Excellent
19	B	13	3/38°	Fall	None	2	52	None	0	–	–	–	–	Excellent	Excellent
20	B	9	3/48°	Fall	None	1	13	none	0	–	–	–	–	Excellent	Excellent

B: Boy, G:Girl, HO: Heterotopic ossification, AVN: Avascular necrosis.

order to obtain adequate reduction, sometimes a percutaneous, minimal invasive, extra-articular K-wire can be used.<sup>21–26</sup> Many studies have reported adequate and satisfactory results obtained using this technique. In a study by Okçu G and Aktuğlu K<sup>22</sup> the carrying angle was found to be equal to that of the opposite extremity in 9 patients with an angulation of >30° who were surgically treated with the percutaneous K-wire aided Métaizeau technique. Radial head enlargement was reported in 5 patients and premature fusion of the physeal plate in 4 patients. However, it was

concluded that these were not functionally significant and with the exception of 1 patient, perfect results were reported for the other 8 patients.

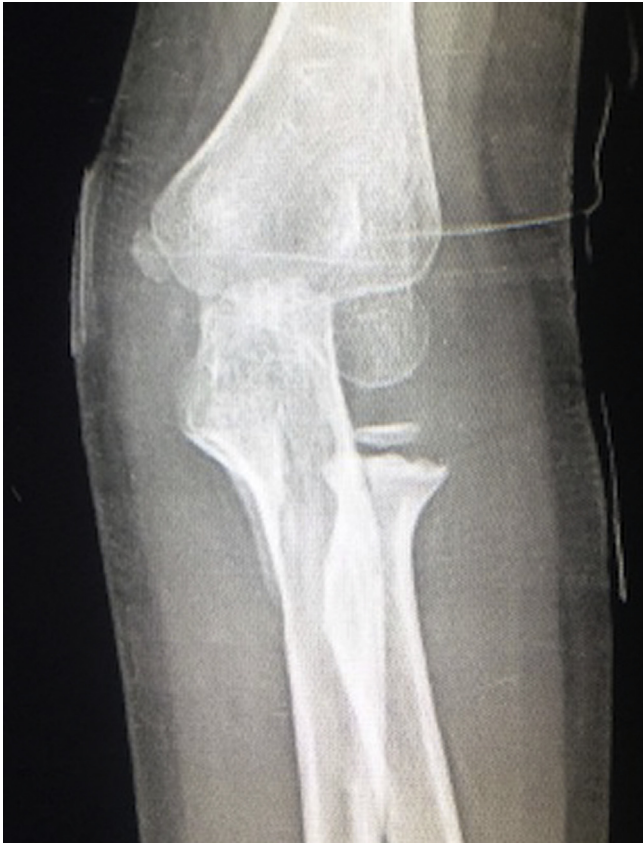Brandão et al<sup>23</sup> reported excellent and good results in 23 of 26 patients with the same method. In 2 of these patients, there was asymptomatic enlargement of the radial head while 1 patient with a concomitant olecranon fracture had heterotopic ossification. In another study of a patient group of 14 Judet Type 4 fractures with a mean angulation of 72.8°, the K-wire aided Métaizeau technique

**Table 6**  
Preoperative and postoperative carrying angles and range of motions.

	Preoperative Radius head angulation	Last control Radius head angulation	Uninjured arm carrying angle	Injured arm carrying angle	Uninjured arm F-E ROM	Injured arm F-E ROM	Uninjured arm S-P ROM	Injured arm S-P ROM
1	35°	Anatomic	11°	11°	145°	145°	166°	166°
2	40°	Anatomic	11.5°	17.5°	148°	133°	160°	160°
3	44°	Anatomic	12°	12°	150°	150°	162°	162°
4	36°	Anatomic	11°	11°	153°	153°	160°	160°
5	85°	10°	8°	18°	147°	147°	166°	166°
6	54°	Anatomic	11.8°	11.8°	142°	142°	155°	155°
7	40°	Anatomic	12.2°	12.2°	148°	148°	158°	158°
8	76°	Anatomic	9.3°	9.3°	150°	150°	164°	164°
9	72°	Anatomic	9.1°	9.1°	153°	153°	172°	172°
10	52°	Anatomic	11.3°	11.3°	147°	147°	170°	155°
11	45°	Anatomic	12.5°	12.5°	142°	142°	158°	158°
12	78°	10°	9.2°	15.2°	151°	151°	174°	174°
13	36°	Anatomic	12.7°	12.7°	152°	152°	161°	161°
14	45°	Anatomic	9.1°	9.1°	150°	150°	173°	173°
15	38°	Anatomic	9.2°	9.2°	145°	145°	171°	171°
16	72°	8°	10.8°	10.8°	148°	148°	166°	166°
17	45°	Anatomic	11.7°	11.7°	151°	151°	164°	164°
18	70°	Anatomic	8.8°	8.8°	144°	144°	170°	170°
19	38°	Anatomic	12.4°	12.4°	145°	145°	164°	164°
20	48°	Anatomic	10.9°	10.9°	147°	147°	172°	172°
<b>p value:</b>	<b>0.001</b>		<b>0.094</b>		<b>0.330</b>		<b>0.330</b>	

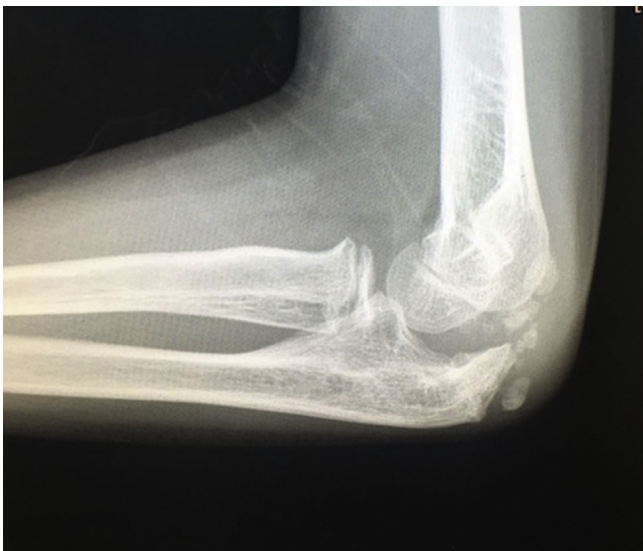Bold indicates the difference between pre and post operative radius head angulation which was found to be statistically significant.

F-E ROM: Flexion-Extension Range of motion, S-P ROM: Supination-Pronation Range of Motion.



**Fig. 4.** Avascular necrosis of radial head. 4 years old boy, Preoperative radial neck angulation was 85°, Judet 4B. Postoperative 34th month x-ray is present.

was used and no complications were recorded associated with radial head enlargement, avascular necrosis or premature fusion of the physal plate. Despite all these satisfying results, some authors believe that the percutaneous K-wire used for closed reduction causes damage to the physis during manipulation.<sup>6</sup> Al-Aubaidi et al<sup>9</sup> used the closed intramedullary method in 10 of 16 patients,



**Fig. 5.** Radial head enlargement and heterotopic ossification of elbow. 6 years old girl, Preoperative radial neck angulation was 78° (Judet 4A) and accompanying olecranon fracture. Postoperative 24th month x-ray is present.

the percutaneous K-wire aided intramedullary method in 4 and open reduction in 2. No difference was observed in respect of complications between the patients treated with the closed method and those who were applied with K-wire aided reduction.

In the current study, premature fusion of the physal plate was observed in 6 patients, radial head avascular necrosis in 1 patient, enlargement of the radial head in 2 patients and heterotopic ossification in 2 patients. Of the patients with premature fusion of the physal plate, 5 were asymptomatic while 1 patient had a limitation of motion of 15°. Similarly, the radial head enlargement in 2 patients was found to be asymptomatic. Considering the complications encountered, since 4 of the 6 patients that had premature fusion of the physal plate had Judet Type 4 fractures and 1 of the 2 patients with radial head enlargement had a Judet Type 4 fracture and the other had an olecranon fracture, these complications can be considered to have resulted from the disruption of the blood supply to the radial head during the trauma. The mean follow-up period of our study was 34.6 months (13–84) and these complications were encountered during this short follow-up. As the follow-up time of the patients increases and epiphyseal plates are closed, these complications may change until maturity.

In this series, the clinical and functional results were found to be excellent in 16 (80%) patients, good in 3 (15%) and fair in 1 (5%) according to the Tibone – Stoltz classification system. In the radiological evaluation according to Ursei, 17 (85%) patients were evaluated as excellent and 3 (15%) as good. All the results obtained in the study were seen to be consistent with the literature.

## Conclusions

From the results of this study and related literature, the use of the Métaizeau technique in displaced radial neck fractures requiring surgical treatment in children can be recommended since it creates minimum damage to the soft tissue, is easy to apply and the results are satisfactory. Therefore we consider that the closed K-wire aided Métaizeau technique can be used as an effective method in the treatment of Judet stage 3 and 4 displaced radial neck fractures in children.

## References

- Eilert RE, Erickson MA. Proximal radius and ulna fractures. In: Beaty JH, Kasser JR, eds. *Rockwood and Wilkins Fractures in Children*. Lippincott Williams & Wilkins; 2010:443–490.
- Canale ST. Fractures and dislocations in children. In: Canale ST, Beaty JH, eds. *Campbell's Operative Orthopaedics*. Mosby/Elsevier; 2011:1531–1725.
- Eberl R, Singer G, Fruhmant J, et al. Intramedullary nailing for the treatment of dislocated pediatric radial neck fractures. *Eur J Pediatr Surg*. 2010;20(04):250–252.
- Pring ME. Pediatric radial neck fractures: when and how to fix. *J Pediatr Orthop*. 2013;32(suppl 1):14–21.
- D'souza S, Vaishya R, Klenerman L. Management of radial neck fractures in children: a retrospective analysis of one hundred patients. *J Pediatr Orthop*. 1992;13(2):232–238.
- Ugutmen E, Ozkan K, Ozkan FU, et al. Reduction and fixation of radius neck fractures in children with intramedullary pin. *J Pediatr Orthop B*. 2010;19(4):289–293.
- De Pellegrin M, Brivio A. Frattura del capitello radiale nel bambino: riduzione e sintesi mini-invasiva. Radial neck fracture in children: minimally invasive reduction and fixation. *Giornale Italiano di Ortopedia e Traumatologia*. 2012;38(1):27–34.
- Tarallo L, Mugnai R, Fiacchi F, et al. Management of displaced radial neck fractures in children: percutaneous pinning vs. elastic stable intramedullary nailing. *J Orthop Traumatol*. 2013;14(4):291–297.
- Al-Aubaidi Z, Pedersen NW, Nielsen KD. Radial neck fractures in children treated with the centromedullary Métaizeau technique. *Injury*. 2012;43(3):301–305.
- Zimmerman RM, Kalish LA, Hresko MT, et al. Surgical management of pediatric radial neck fractures. *J Bone Joint Surg Am*. 2013;95(20):1825–1832.
- Herring JA. *Tachdjian's Pediatric Orthopaedics*. 4th ed. Philadelphia: Saunders Elsevier; 2008.
- Judet J, Judet R, Lefranc J. Fracture of the radial head in the child. *In Ann de chirurgie*. 1962;16:1377–1385.

13. Métaizeau JP, Lascombes P, Lemelle JL, et al. Reduction and fixation of displaced radial neck fractures by closed intramedullary pinning. *J Pediatr Orthop.* 1993;13(3):355–360.
14. Métaizeau JP, Prevot J, Schmitt M. Reduction and fixation of fractures of the neck of the radius by centro-medullary pinning. Original technic. *Rev Chir Orthop Reparatrice Appar Mot.* 1980;66(1):47–49.
15. Ursei M, De Gauzy JS, Knorr J, et al. Surgical treatment of radial neck fractures in children by intramedullary pinning. *Acta Orthop Belg.* 2006;72(2):131.
16. Tibone JE, Stoltz M. Fractures of the radial head and neck in children. *J Bone Joint Surg Am.* 1981;63(1):100–106.
17. Antony AS. Fractures of the neck of radius in children. In: Morrey BF, ed. *Morrey's The Elbow and its Disorders.* Saunders; 2009:268–282.
18. Steinberg EL, Golomb D, Salama R, et al. Radial head and neck fractures in children. *J Pediatr Orthop.* 1988;8(1):35–40.
19. Bernstein SM, McKeever P, Bernstein L. Percutaneous reduction of displaced radial neck fractures in children. *J Pediatr Orthop.* 1993;13(1):85–88.
20. Steele JA, Graham HK. Angulated radial neck fractures in children. A prospective study of percutaneous reduction. *Bone Joint J.* 1992;74(5):760–764.
21. Schmittenbecher PP, Haevernick B, Herold A, et al. Treatment decision, method of osteosynthesis, and outcome in radial neck fractures in children: a multi-center study. *J Pediatr Orthop.* 2005;25(1):45–50.
22. Okcu G, Aktuğlu K. Surgical treatment of displaced radial neck fractures in children with Métaizeau technique. *Turkish J Trauma Emerg Surg.* 2007;13(2):122–127.
23. Brandão GF, Soares CB, Teixeira LEM, et al. Displaced radial neck fractures in children: association of the Métaizeau and Böhler surgical techniques. *J Pediatr Orthop.* 2010;30(2):110–114.
24. Bither N, Gupta P, Jindal N. Pediatric displaced radial neck fractures: retrospective results of a modified Métaizeau technique. *Eur J Orthop Surg Traumatol.* 2015;25(1):99–103.
25. Koca K, Erdem Y, Neyişçi Ç, et al. Intramedullary elastic nailing of the displaced radial neck fractures in children. *Acta Orthop Traumatol Turc.* 2017;51(6):451–454.
26. Cha SM, Shin HD, Kim KC, et al. Percutaneous reduction and leverage fixation using K-wires in paediatric angulated radial neck fractures. *Int Orthop.* 2012;36(4):803–809.