

## Subacromial space volume in patients with rotator cuff tear: The effect of surgical repair

Murad Pepe <sup>a,\*</sup>, Onur Kocadal <sup>b</sup>, Zafer Gunes <sup>c</sup>, Emre Calisal <sup>a</sup>, Ertugrul Aksahin <sup>d</sup>, Cem Nuri Aktekin <sup>e</sup>

<sup>a</sup> Department of Orthopaedics and Traumatology, University of Amasya, Amasya, Turkey

<sup>b</sup> Department of Orthopaedics and Traumatology, University of Yeditepe, Istanbul, Turkey

<sup>c</sup> Department of Orthopaedics and Traumatology, Ankara Training and Research Hospital, Ankara, Turkey

<sup>d</sup> Orthopaedics and Traumatology, Medical Park Hospital, Ankara, Turkey

<sup>e</sup> Department of Orthopaedics and Traumatology, Ankara Yildirim Beyazit University, Ankara, Turkey

### ARTICLE INFO

#### Article history:

Received 17 April 2017

Received in revised form

12 May 2018

Accepted 29 August 2018

Available online 27 September 2018

#### Keywords:

Subacromial space

Volumetric analysis

MR imaging

Rotator cuff tear

Full-thickness tear

Single-row repair

### ABSTRACT

**Objective:** The aim of this study was to evaluate the effect of the rotator cuff tear repair on subacromial space volume.

**Methods:** We retrospectively identified 21 eligible patients (5 males and 16 females; mean age: 56.4 (range; 46–71) years) who had shoulder arthroscopy for unilateral full-thickness small to medium rotator cuff tear and normal contralateral shoulder joint. The mean follow-up time was 16.1 (range; 12–25) months. Preoperative and postoperative 1 year bilateral shoulder MRIs and Constant scores were reviewed. Subacromial volume was calculated by using Osirix software. Pre-, postoperative and healthy side (contralateral control group) subacromial volumes were recorded. Paired sample and t-tests were used to compare the pre- and postoperative groups. Independent sample t-tests were used to compare the healthy and pre- and postoperative groups. The correlation between the changes in the subacromial volume and the shoulder Constant score were analyzed using Pearson correlation analyses.

**Results:** The mean subacromial volume of the preoperative group was 2.95 cm<sup>3</sup> (range; 1.53–4.23) and the postoperative group was 3.59 cm<sup>3</sup> (range; 2.12–4.84). The volume increase was statistically significant ( $p < 0.05$ ). The mean subacromial volume of the control group was 3.93 cm<sup>3</sup> (range; 2.77–5.03), and the difference between the preoperative group and the control group was statistically significant. There was no significant difference found between the postoperative group and the control group ( $p = 0.156$ ). There was no significant correlation found between the volume and the constant score changes ( $r = 0.170$ ,  $p = 0.515$ ).

**Conclusion:** The subacromial space volume significantly decreases in full-thickness rotator cuff tears smaller than 3 cm and the surgical repair increases the subacromial volume significantly.

**Level of evidence:** Level IV; Diagnostic Study.

© 2018 Turkish Association of Orthopaedics and Traumatology. Publishing services by Elsevier B.V. This is an open access article under the CC BY-NC-ND license (<http://creativecommons.org/licenses/by-nc-nd/4.0/>).

### Introduction

Rotator cuff (RC) tears are very common disorders of the shoulder joint. Intrinsic and extrinsic factors are accused of the

aetiology of the tendon tears.<sup>1–3</sup> Tendon vascularization, age, smoking, genetic predisposition, and overuse are leading to intrinsic factors.<sup>1,4–7</sup> The most important extrinsic factor is acromial morphology that leads narrowing of the subacromial region and causes mechanical compression of RC. Over 40 years past from the blaming of the acromion spur which cause the RC pathology by Neer et al to the present; Bigliani classified the acromion shape into three different patterns, and then several researchers have mentioned the different angles, lengths, and indexes between acromion and scapular structures at the shoulder joint which can

\* Corresponding author. Amasya University, School of Medicine, Department of Orthopaedics and Traumatology, Amasya, 05100, Turkey. Tel.: +90 5458571807.

E-mail address: [dr\\_muradpepe@hotmail.com](mailto:dr_muradpepe@hotmail.com) (M. Pepe).

Peer review under responsibility of Turkish Association of Orthopaedics and Traumatology.

affect the RC.<sup>8–15</sup> Many researchers have associated the relationship between extrinsic parameters and RC pathology with the narrowing of the subacromial space. Acromiohumeral distance (AHD) is commonly used to measure the size of the subacromial space.<sup>16</sup> AHD < 6 mm indicates the full-thickness RC tear with the high specificity.<sup>17</sup> The reduced AHD is explained by humeral head ascension as a result of the torn and retracted RC.<sup>18</sup> AHD has also prognostic interest as well as the diagnostic. Loss of the normal acromiohumeral distance is a sign of poor prognosis following RC tear repair.<sup>18,19</sup> However, poor reliability was reported for the AHD measurement.<sup>20–23</sup> Variables such as x-ray standardization, measurement technique, and patient position may influence reliability.<sup>16</sup> When the three-dimensional structure of the subacromial region is considered, two-dimensional plan measurement may be insufficient in determining the narrowing.<sup>16</sup> Therefore, volumetric analysis of the subacromial region has recently been discussed.<sup>24</sup>

In our study, we aimed to investigate the relationship between the subacromial volume and the rotator cuff tear. For this reason, we tested three hypotheses. The first hypothesis was that the subacromial volume would be decreased with the full-thickness rotator cuff tears when compared with the healthy side. The second hypothesis was that the subacromial volume would be increased following rotator cuff tear repair. The third hypothesis was that there would be significant relationship between the subacromial volume change and clinic outcome in RC tear repair.

## Materials and methods

We retrospectively surveyed the shoulder arthroscopy archive and retrieved the patients who had arthroscopically operated because of the unilateral full-thickness rotator cuff tears with a single-row method between January 2013 and December 2015. Preoperative demographic data, magnetic resonance imaging (MRI), shoulder Constant score and tear size smaller than 3 cm (small to medium tear) were inclusion criteria. Grade 3–4 fatty degeneration (Goutallier classification), concomitant subacromial acromioplasty (bony spur removal or trimming), hooked type acromion, double-row repairs, traumatic tears, shoulder instability, acromioclavicular and glenohumeral osteoarthritis, ischemic necrosis, history of previous shoulder fracture or surgery, labral lesions, adhesive capsulitis were excluded. Surgeries were performed by an experienced shoulder surgeon (CNA) in the beach-chair position with the routine arthroscopic portals. For tears, two suture anchors were used at both the medial row and the lateral row in the single-row repair. Shoulder sling with abduction pillow was applied and gentle passive flexion and abduction exercises were started on the day after surgery. The sling was removed, and the active range of motion exercise was started in 6 weeks.

We invited the patient who had completed one year of surgery for outpatient control. The non-operated shoulder was examined. Patient with normal physical examination and without prior shoulder fracture, dislocation or surgical history was informed about the study, and bilateral shoulder MRI was taken, and the final Constant score was recorded. Pre-, postoperative and healthy side (control group) subacromial volumes were calculated. This study was reviewed and approved by the ethics committee (ID number: 0657/2016).

### MRI evaluation

MRI was performed using a 1.5 T MR-Scanner (Magnetom Aera, Siemens AG, Erlangen, Germany). The patient's examination was done in a supine position with the arm at the side, hand palm facing upward to prevent the shoulder motion. Coronal, sagittal, and axial T1-weighted images were acquired for structural assessment of the

acromion and humeral head; T2-weighted images were acquired for qualitative assessment of the rotator cuff tendon. The slice thickness was 4 mm.

### Measurement

Subacromial volume was calculated by using Osirix software (Pixmeo, Geneva, Switzerland). To standardize the measurements, T1-weighted sagittal images that bone tissue appears better were used. The area between the undersurface of the acromion and the chondral surface of the humeral head was outlined using the pencil tool on serial sagittal T1-weighted images from the acromial tip to the acromioclavicular joint. Then the program computed the volume automatically regarding cm<sup>3</sup> (Fig. 1). Radiologic measurements were done by the first author. The second author also measured all the radiologic parameters to avoid any inter-rater errors. Measurements were repeated by the same authors 2 weeks after the first ones to evaluate intra-rater reliability. Intra-class coefficient correlations (ICCs) were used to assess reliability.

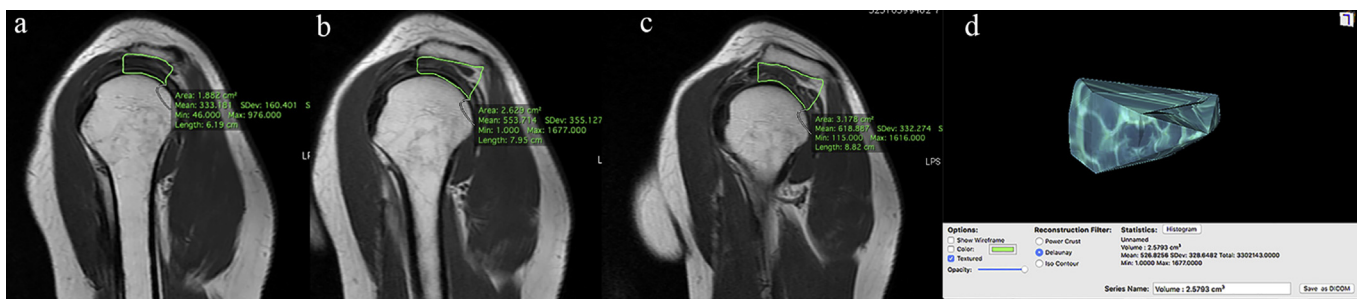
### Statistical analyses

The statistical analysis was carried out using the SPSS for MAC OS X program (version 20; SPSS Inc.). Paired sample t-test was used to compare the preoperative and postoperative shoulder subacromial volume. Independent sample t-test was used to compare the control and the preoperative and the postoperative shoulder subacromial volume. The correlation between the changes in the subacromial volume and the shoulder Constant score were analyzed using Pearson correlation analyses. A p value < 0.05 was considered statistically significant. Intra-class correlation coefficient (ICC, varied between 0 and 1) with 95% confidence intervals was used to evaluate the intra- and inter-observer reliability for subacromial volume measurement.

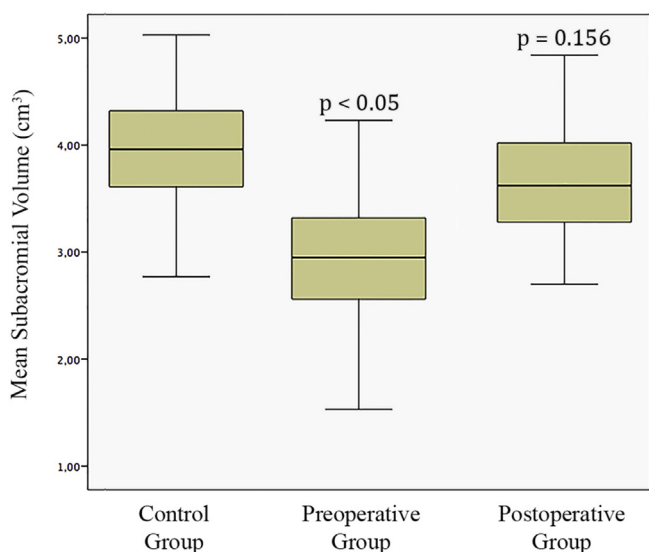
Power analyses were performed using the G-power 3.1 statistical analysis program. To estimate the required sample size, the effect size and the alpha, power (1-beta) were used. These were 0.6, 0.05, 0.8, respectively. The sample size required for each group is 19. We used 21 samples in each group to avoid being under power.

## Results

A total of 21 patients were eligible for the study. Five of these patients (23.8%) were male, whereas 16 patients (76.2%) were female. The average age was 56.4 (range; 46–71) years. Right shoulder was affected in 15 patients, and the left side was affected in 6 patients. The mean follow-up time was 16.1 (range; 12–25) months. The mean subacromial volume of the control group was 3.93 cm<sup>3</sup> (range; 2.77–5.03), the preoperative group was 2.95 cm<sup>3</sup> (range; 1.53–4.23) and the postoperative group was 3.59 cm<sup>3</sup> (range; 2.12–4.84) (Fig. 2). The difference between the preoperative group and the control group was statistically significant (p < 0.05). There was no statistically significant difference between the postoperative and the control group (p = 0.156). The statistically significant difference was found between the preoperative and the postoperative group (p < 0.05). The mean constant score of the patients increased from 38.3 (range; 19–57) at preoperatively to the 75.6 (range; 53–89) at postoperative 1-year. When we consider the correlation analysis between shoulder volume and shoulder constant score changes, no significant correlation was found between the volume changes and constant score changes (r = 0.170, p = 0.515). The intra-observer reliability was 0.975, and the inter-observer reliability was 0.913 for the subacromial volume measurements.



**Fig. 1.** Subacromial volume measurement obtained using a computer-assisted method. At each image (a, b, c), subacromial space margins were outlined by pencil tool and then (d) volume was computed automatically by program in terms of cm<sup>3</sup>.



**Fig. 2.** Diagram showing the mean subacromial volume of control, preoperative and postoperative group. P values illustrated to show differences relative to control group.

**Discussion**

The formation and development process of rotator cuff pathologies are multifactorial.<sup>15</sup> Among them, the role of extrinsic factors is still being debated.<sup>24,25</sup> Extrinsic factors include acromion spurs, acromioclavicular joint arthritis, thoracic kyphosis, scapular dyskinesia, abnormal shoulder muscle activity, and reduced coracoacromial canal area.<sup>26–29</sup> The most important structure that authors focus on extrinsic factors is acromion morphology.<sup>30</sup> Hook type acromion is the most associated anatomic variation with tear and narrowing of the subacromial region is accused of the mechanism.<sup>28,31</sup> The narrowing in the subacromial region can be determined by direct or indirect measurement methods. Indirect methods include acromion anterior slope (AAS), lateral acromial angle (LAA), acromion index (AI), acromio-glenoid angle (AGA) and critical shoulder angle (CSA).<sup>11,13,15,32,33</sup> These measurement methods reveal the altered acromial morphology and indirectly show the narrowing in the subacromial region. High slope angle, low LAA values, and increased AI were also associated with RC tears.<sup>15,33–35</sup> Tetreault et al pointed out that low AGA values show the narrowed supraspinatus outlet.<sup>35</sup> The theory is that these measurement parameters show a reduced subacromial space. Chopp-Hurley et al reported that there is poor to moderate correlation between these morphological characteristics and subacromial width.<sup>36</sup> Balke et al showed in their studies that acromion morphology in degenerative RCTs differs from traumatic RCTs. They

reported that the subacromial space narrowed in degenerative but remained intact in traumatic tears.<sup>15</sup> For this reason, we included degenerative RC tears in our study.

The subacromial space size is directly measured by the distance between the humeral head and the acromion. This measurement is termed acromiohumeral distance (AHD). Goutallier et al has reported that acromiohumeral distance below 6 mm is at high risk for degenerative RC tears.<sup>17</sup> Saupé et al demonstrated that reduced AHD is associated with the fatty degeneration (FD) of the RC muscles.<sup>12</sup> FD is the predictor of the poor functional results after RC tear repair.<sup>37</sup> Measurement methodology (different landmark selection) and radiography standardization (patient position, different X-ray beam angle) may influence the reliability of AHD.<sup>16,20,38</sup> McCreesh noted that the evaluation of the three-dimensional structure of the subacromial space with two-dimensional radiographs may cause such reliability problems.<sup>16</sup> The relation between the subacromial volume and RC pathologies was first investigated by Yi et al.<sup>24</sup> The mean subacromial volume was found 2.27 cm<sup>3</sup> in partial tears, 2.37 cm<sup>3</sup> in full-thickness tears, 2.58 cm<sup>3</sup> in control group and no significant differences were found between these groups.<sup>24</sup> We found the mean subacromial volume is significantly reduced in preoperative group (mean; 2.95 cm<sup>3</sup>, range; 1.53–4.23) than control group (mean; 3.93 cm<sup>3</sup>, range; 2.77–5.03). However, Yi comprised the control group patients who have shoulder instability without any subacromial pathology in their study. We included the contralateral healthy shoulders as the control group. In addition, Yi first measured the cross-sectional area and then multiply it with depth to calculate the subacromial volume. On the contrary to Yi, we have determined the bone margins of the subacromial region in the sections, and then the system automatically computes the volume. We also measured postoperative volume in our study and found that the volume increased (mean; 3.59 cm<sup>3</sup>, range; 2.12–4.84) significantly after treatment. However, no significant difference was found between the postoperative group and the control group.

Superior migration of the humeral head is commonly encountered in the retracted late-stage full-thickness RC tear. In the lack of the rotator cuff, the predominance of deltoid muscle pull is shown as the reason for the upward migration of the humeral head.<sup>12</sup> Superior migration of the humeral head causes a decrease in the subacromial volume. In our study, we included small to medium full-thickness RC tears. The significant subacromial volume decrease in early-stage tears indicates that humeral head migration begins with the development of the RC tears. The significant volume increase after treatment indicates that the humeral head downward migration. The reason for this migration may be the normalization of the deltoid muscle pull dominance with the restoration of the rotator cuff function.

When we analyze the correlation between the clinical score and the subacromial volume, no significant difference was found. We

attribute to reason that multiple factors play a role in the healing process as well as in the formation of RC tears.

There are some limitations of our study. The number of patients was limited. However, our sample size was overpowered. We tried to exclude traumatic tears by the anamnesis of the patients. Tears affected by extrinsic factors start on the bursal side of the RC. However, since we used full-thickness tears in our study, we did not have any information about whether the tear is beginning from the bursal or the articular side.

## Conclusions

Based on the results of our study, the first and second hypothesis can be accepted whereas third can be rejected. The subacromial space volume significantly decreases in full-thickness rotator cuff tears smaller than 3 cm and significantly increases after single-row repair technique. The repair of early-stage full thickness RC tears allows for subacromial volume reach to normal shoulder subacromial volume level.

## References

- Biberthaler P, Wiedemann E, Nerlich A, et al. Microcirculation associated with degenerative rotator cuff lesions. *J Bone Joint Surg Am.* 2003;85(3):475–480.
- Chambler AFW, Pitsillides AA, Emery RJH. Acromial spur formation in patients with rotator cuff tears. *J Shoulder Elbow Surg.* 2003;12(4):314–321. [https://doi.org/10.1016/S1058-2746\(03\)00030-2](https://doi.org/10.1016/S1058-2746(03)00030-2).
- Fukuda H, Hamada K, Yamanaka K. Pathology and pathogenesis of bursal-side rotator cuff tears viewed from en bloc histologic sections. *Clin Orthop Relat Res.* 1990;254:75–80.
- Gumina S, Carbone S, Campagna V, Candela V, Sacchetti FM, Giannicola G. The impact of aging on rotator cuff tear size. *Musculoskelet Surg.* 2013;97(1):69–72. <https://doi.org/10.1007/s12306-013-0263-2>.
- Carbone S, Gumina S, Arceri V, Campagna V, Fagnani C, Postacchini F. The impact of preoperative smoking habit on rotator cuff tear: cigarette smoking influences rotator cuff tear sizes. *J Shoulder Elbow Surg.* 2012;21(1):56–60. <https://doi.org/10.1016/j.jse.2011.01.039>.
- Almekinders LC, Weinhold PS, Maffulli N. Compression etiology in tendinopathy. *Clin Sports Med.* 2003;22(4):703–710. [https://doi.org/10.1016/S0278-5919\(03\)00067-X](https://doi.org/10.1016/S0278-5919(03)00067-X).
- Mayerhoefer ME, Breitenseher MJ, Wurnig C, Roposch A. Shoulder impingement: relationship of clinical symptoms and imaging criteria. *Clin J Sport Med.* 2009;19(2):83–89. <https://doi.org/10.1097/JSM.0b013e318198e2e3>.
- Neer CS. Anterior acromioplasty for the chronic impingement syndrome in the shoulder. *J Bone Joint Surg Am.* 1972;54(1):41–50.
- Bigliani LU, Ticker JB, Flatow EL, Soslowsky LJ, Mow VC. The relationship of acromial architecture to rotator cuff disease. *Clin Sports Med.* 1991;10(4):823–838.
- Bigliani LU. The morphology of the acromion and its relationship to rotator cuff tears. *Orthop Trans.* 1986;10:459–460.
- Kitay GS, Iannotti JP, Williams GR, Haygood T, Kneeland BJ, Berlin J. Roentgenographic assessment of acromial morphologic condition in rotator cuff impingement syndrome. *J Shoulder Elbow Surg.* 1995;4(6):441–448.
- Saue N, Pfirrmann CWA, Schmid MR, Jost B, Werner CML, Zanetti M. Association between rotator cuff abnormalities and reduced acromiohumeral distance. *Am J Roentgenol.* 2006;187(2):376–382. <https://doi.org/10.2214/AJR.05.0435>.
- Banas MP, Miller RJ, Totterman S. Relationship between the lateral acromion angle and rotator cuff disease. *J Shoulder Elbow Surg.* 1995;4(6):454–461.
- Moor BK, Bouaicha S, Rothenfluh DA, Sukthankar A, Gerber C. Is there an association between the individual anatomy of the scapula and the development of rotator cuff tears or osteoarthritis of the glenohumeral joint? *Bone Joint J.* 2013;95(7):935–941. <https://doi.org/10.1302/0301-620X.95B7.31028>.
- Balke M, Liem D, Greshake O, Hoeher J, Bouillon B, Banerjee M. Differences in acromial morphology of shoulders in patients with degenerative and traumatic supraspinatus tendon tears. *Knee Surg Sports Traumatol Arthrosc.* 2016;24(7):2200–2205. <https://doi.org/10.1007/s00167-014-3499-y>.
- McCreesh KM, Crotty JM, Lewis JS. Acromiohumeral distance measurement in rotator cuff tendinopathy: is there a reliable, clinically applicable method? A systematic review. *Br J Sports Med.* 2015;49(5):298–305. <https://doi.org/10.1136/bjsports-2012-092063>.
- Goutallier D, Le Guilloux P, Postel JM, Radier C, Bernageau J, Zilber S. Acromio humeral distance less than six millimeter: its meaning in full-thickness rotator cuff tear. *Orthop Traumatol Surg Res.* 2011;97(3):246–251. <https://doi.org/10.1016/j.otsr.2011.01.010>.
- Nové-Josserand L, Edwards TB, O'Connor DP, Walch G. The acromiohumeral and coracohumeral intervals are abnormal in rotator cuff tears with muscular fatty degeneration. *Clin Orthop Relat Res.* 2005;433:90–96. <https://doi.org/10.1097/01.blo.0000151441.05180.0e>.
- Walch G, Marechal E, Maupas J, Liotard J. Surgical treatment of rotator cuff rupture. Prognostic factors. *Rev Chir Orthop Reparatrice Appar Mot.* 1992;78(6):379–388.
- Bernhardt G, Glehr M, Zacherl M, Wurnig C, Gruber G. Observer variability in the assessment of the acromiohumeral interval using anteroposterior shoulder radiographs. *Eur J Orthop Surg Traumatol.* 2013;23(2):185–190. <https://doi.org/10.1007/s00590-012-0942-y>.
- Gruber G, Bernhardt GA, Clar H, Zacherl M, Glehr M, Wurnig C. Measurement of the acromiohumeral interval on standardized anteroposterior radiographs: a prospective study of observer variability. *J Shoulder Elbow Surg.* 2010;19(1):10–13. <https://doi.org/10.1016/j.jse.2009.04.010>.
- Giphart JE, van der Meijden OA, Millett PJ. The effects of arm elevation on the 3-dimensional acromiohumeral distance: a biplane fluoroscopy study with normative data. *J Shoulder Elbow Surg.* 2012;21(11):1593–1600. <https://doi.org/10.1016/j.jse.2011.11.023>.
- Kalra N, Seitz AL, Boardman III ND, Michener LA. Effect of posture on acromiohumeral distance with arm elevation in subjects with and without rotator cuff disease using ultrasonography. *J Orthop Sports Phys Ther.* 2010;40(10):633–640. <https://doi.org/10.2519/jospt.2010.3155>.
- Yi A, Avramis IA, Argintar EH, White ER, Villacs DC, Hatch III GFR. Subacromial volume and rotator cuff tears: does an association exist? *Indian J Orthop.* 2015;49(3):300–303. <https://doi.org/10.4103/0019-5413.156201>.
- Giai Via A, De Cupis M, Spoliti M, Oliva F. Clinical and biological aspects of rotator cuff tears. *Muscles Ligaments Tendons J.* 2013;3(2):70–79. <https://doi.org/10.11138/mltj/2013.3.2.070>.
- Harryman DT, Sidles JA, Clark JM, McQuade KJ, Gibb TD, Matsen FA. Translation of the humeral head on the glenoid with passive glenohumeral motion. *J Bone Joint Surg Am.* 1990;72(9):1334–1343.
- Moraes GFS, Faria CDCM, Teixeira-Salmela LF. Scapular muscle recruitment patterns and isokinetic strength ratios of the shoulder rotator muscles in individuals with and without impingement syndrome. *J Shoulder Elbow Surg.* 2008;17(1):48–53. <https://doi.org/10.1016/j.jse.2007.08.007>.
- Gumina S, Arceri V, Fagnani C, et al. Subacromial space width: does overuse or genetics play a greater role in determining it? *J Bone Joint Surg Am.* 2015;97(20):1647–1652. <https://doi.org/10.2106/JBJS.O.00379>.
- Hébert LJ, Moffet H, McFadyen BJ, Dionne CE. Scapular behavior in shoulder impingement syndrome. *Arch Phys Med Rehabil.* 2002;83(1):60–69. <https://doi.org/10.1053/apmr.2002.27471>.
- Balke M, Schmidt C, Dedy N, Banerjee M, Bouillon B, Liem D. Correlation of acromial morphology with impingement syndrome and rotator cuff tears. *Acta Orthop.* 2013;84(2):178–183. <https://doi.org/10.3109/17453674.2013.773413>.
- Le Reun O, Lebhar J, Mateos F, Voisin JL, Thomazeau H, Ropars M. Anatomical and morphological study of the subcoracoacromial canal. *Orthop Traumatol Surg Res.* 2016;102(8):295–299. <https://doi.org/10.1016/j.otsr.2016.08.001>.
- Torrens C, López J-M, Puente I, Cáceres E. The influence of the acromial coverage index in rotator cuff tears. *J Shoulder Elbow Surg.* 2007;16(3):347–351. <https://doi.org/10.1016/j.jse.2006.07.006>.
- Nyffeler RW, Werner CML, Sukthankar A, Schmid MR, Gerber C. Association of a large lateral extension of the acromion with rotator cuff tears. *J Bone Joint Surg Am.* 2006;88(4):800–805. <https://doi.org/10.2106/JBJS.D.03042>.
- Tuite MJ, Toivonen DA, Orwin JF, Wright DH. Acromial angle on radiographs of the shoulder: correlation with the impingement syndrome and rotator cuff tears. *AJR Am J Roentgenol.* 1995;165(3):609–613.
- Têtreault P, Krueger A, Zurakowski D, Gerber C. Glenoid version and rotator cuff tears. *J Orthop Res.* 2004;22(1):202–207. [https://doi.org/10.1016/S0736-0266\(03\)00116-5](https://doi.org/10.1016/S0736-0266(03)00116-5).
- Chopp-Hurley JN, O'Neill JM, Dickerson CR. Distribution of bone and tissue morphological properties related to subacromial space geometry in a young, healthy male population. *Surg Radiol Anat.* 2016;38(1):135–146. <https://doi.org/10.1007/s00276-015-1529-1>.
- Goutallier D, Postel J, Lavau L, Bernageau J. Impact of fatty degeneration of the supraspinatus and infraspinatus muscles on the prognosis of surgical repair of the rotator cuff. *Rev Chir Orthop Reparatrice Appar Mot.* 1999;85(7):668–676.
- Fehring EV, Rospal CE, Rhodes DA, et al. The radiographic acromiohumeral interval is affected by arm and radiographic beam position. *Skeletal Radiol.* 2008;37:535–539. <https://doi.org/10.1007/s00256-008-0467-y>.