


Contents lists available at [ScienceDirect](#)

Acta Orthopaedica et Traumatologica Turcica

journal homepage: <https://www.elsevier.com/locate/aott>

Meniscal allograft transplantation for symptomatic knee after meniscectomy of torn discoid medial meniscus: Report of three cases



Sung Il Wang

Chonbuk National University Medical School, Research Institute of Clinical Medicine of Chonbuk National University, Biomedical Research Institute of Chonbuk National University Hospital, Jeonju, Republic of Korea

ARTICLE INFO

Article history:

Received 17 February 2016

Received in revised form

30 April 2016

Accepted 11 June 2016

Available online 14 October 2016

Keywords:

Bilateral discoid medial meniscus

Re-teared meniscus

Degeneration of cartilage

Meniscus allograft transplantation

ABSTRACT

In symptomatic discoid medial meniscus, partial meniscectomy is the principal treatment method and can yield promising short-term results. However, unlike the nondiscoid meniscus, discoid medial meniscus is frequently associated with horizontal cleavage tears, attributable to the presence of myxoid degeneration in the intrameniscal substance, in that it may potentially occur deteriorating long-term results because of re-tearing of remaining meniscus or secondary degeneration of cartilage of the medial compartment after meniscectomy. We experienced three rare cases of re-tear or secondary degeneration of cartilage of the medial compartment after meniscectomy for two patients with torn bilateral meniscus. Both patients were highly active young males. Meniscal allograft transplantation in complicated discoid medial meniscus was performed. At 2 years after meniscal allograft transplantation, clinical outcomes were improved with a normal range of motion. Orthopedic surgeons should recommend activity modification to prevent possible complicated injury of the discoid medial meniscus. Meniscal allograft transplantation may be an alternative option in highly active young patients undergoing complicated discoid medial meniscus to diminish pain, improve knee function, and prevent or delay degeneration.

© 2016 Turkish Association of Orthopaedics and Traumatology. Publishing services by Elsevier B.V. This is an open access article under the CC BY-NC-ND license (<http://creativecommons.org/licenses/by-nc-nd/4.0/>).

Introduction

The discoid medial meniscus is a rare anatomical variant in which the normal thin and crescent-shaped cartilage is replaced by a thickened and fuller shape that does not taper fully towards the midline. Bilateral cases are more rare, with only 20 cases of bilateral discoid medial meniscus reported.¹ While the anomaly itself is generally asymptomatic, a combination of reduced blood supply, increased thickness and a potentially weak capsular attachment is thought to increase the risk of tearing as compared to the normal variant. This anomaly can be diagnosed at any age, but is generally diagnosed in young subjects with considerable functional and athletic demands.^{1,2} In symptomatic discoid medial meniscus, partial meniscectomy and peripheral side repair as necessary is typically recommended, with good short-term follow-up results.^{3,4} Resection of almost the entire discoid meniscus is sometimes necessary

because of the complexity and extent of the tear or re-tear after partial meniscectomy. Meniscal allograft transplantation (MAT) was developed as a means of treating the symptoms of compartmental overload after total meniscectomy, with improvement in knee function at short- and midterm follow-up, as well as acceptable complication and failure rates.⁵

Here, we experienced two rare cases of bilateral discoid medial meniscus with long-term follow-up. The three involved knees represented re-tear or secondary degeneration of cartilage of the medial compartment after meniscectomy. Both patients were highly active young males, in whom MAT in complicated discoid medial meniscus was performed.

Case reports

Patient 1

In February 2008, an 18-year-old male presented with pain and locking of the left knee that had developed abruptly. He had sustained a twisting injury of his left knee joint while playing

E-mail address: wsi1205@naver.com.

Peer review under responsibility of Turkish Association of Orthopaedics and Traumatology.

<http://dx.doi.org/10.1016/j.aott.2016.09.001>

1017-995X/© 2016 Turkish Association of Orthopaedics and Traumatology. Publishing services by Elsevier B.V. This is an open access article under the CC BY-NC-ND license (<http://creativecommons.org/licenses/by-nc-nd/4.0/>).

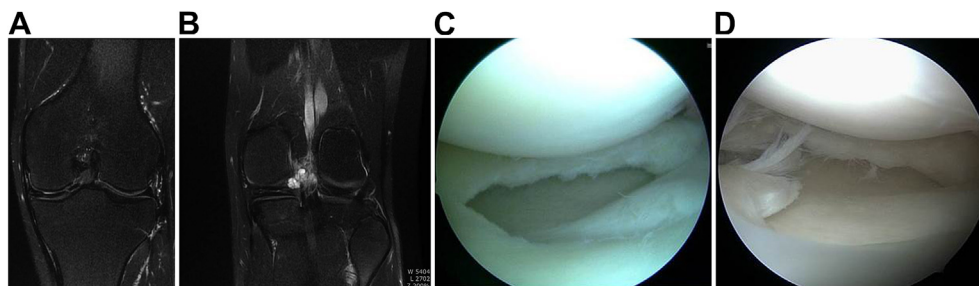


Fig. 1. MRI and arthroscopic images of an 18-year-old male (patient 1) who presented with left knee pain and locking. (a) Coronal T2-weighted image showing meniscus tear with degeneration of the white–white zone. (b) Coronal T2-weighted image showing horizontal tear with cyst formation in the posterior horn of the medial meniscus. (c) The complex torn meniscus was partially resected. (d) Arthroscopic image obtained 4 years after partial meniscectomy showing a re-tear of the remaining medial meniscus extending from the body to the posterior horn.

soccer. Physical examination revealed medial joint line tenderness and positive McMurray's sign, with a normal range of movements. Ligamentous instability and patellofemoral symptoms were not present. No abnormality was observed on radiographs. Magnetic resonance imaging (MRI) revealed a complex tear of the incomplete discoid medial meniscus with cystic changes around the posterior horn (Fig. 1a and b). Partial meniscectomy for torn discoid medial meniscus was performed (Fig. 1c). In January 2012, he presented with pain in both knees aggravated by climbing stairs and long-distance walking as part of his role as a professional soldier. Physical examination revealed joint tenderness and medial pain in McMurray's test in both knees. Arthroscopy of the left knee revealed complex tears of the remaining meniscus extending from its body to the posterior horn. The meniscus had a horizontal cleavage extending to the peripheral rim accompanied by fatty degeneration (Fig. 1d). Arthroscopic subtotal meniscectomy was performed for the discoid medial meniscus. MRI of the right knee revealed an incompletely torn discoid medial meniscus with cleavage tear, and cystic change from the anterior horn to posterior horn. Arthroscopic partial meniscectomy and repair of some parts of the horizontal cleavage site were performed. However, 24 months after subtotal meniscectomy on the left knee, he had difficulties in daily activities and occupation due to the persistent pain in the medial compartment of the left knee joint. A plain radiograph showed a mild narrowing and marginal osteophyte in the left-knee medial compartment (Fig. 2a). No malalignment was detected on standing orthoroentgenogram. MAT was performed using the double bone-plug technique (Fig. 2b).⁶ The size of MAT was

measured by the surgeon as described by previously⁷ and then a fresh-frozen medial meniscal allograft sterilized by BioCleanse processing was provided from the Cellumed tissue bank.

Twelve months after MAT, MRI on the left knee meniscus allograft showed secure integration of the allograft with the joint capsule and good positioning in relation to the tibiofemoral joint (Fig. 3). Two years after MAT on the left knee, clinical outcome was a visual analog scale score of 2, Lysholm score of 76 and Tegner activity scale level 5, with a normal range of movement.

Patient 2

In April 2010, a 21-year-old male professional soldier was referred to our hospital for a 2-month history of pain and swelling in both knees. He had a history of acute injury while running and jumping. The symptoms were worsened by long-distance walking and participation in sports activities. Physical examination revealed tenderness of the medial joint line bilaterally. The left knee featured pain and a locking sensation upon full extension. MRI revealed complete discoid medial meniscus with a complex tear bilaterally (Fig. 4a and b). Furthermore, a degenerative longitudinal tear was observed extending from the body portion to the posterior horn on the peripheral side in the right knee (Fig. 4c). Subtotal meniscectomy was performed to treat the severe marginal degeneration and fatty degeneration in the right knee. Partial meniscectomy involving the flap torn meniscus was performed in the left knee. For the inner horizontal cleavage tear, the inferior surface was also removed (Fig. 4d).

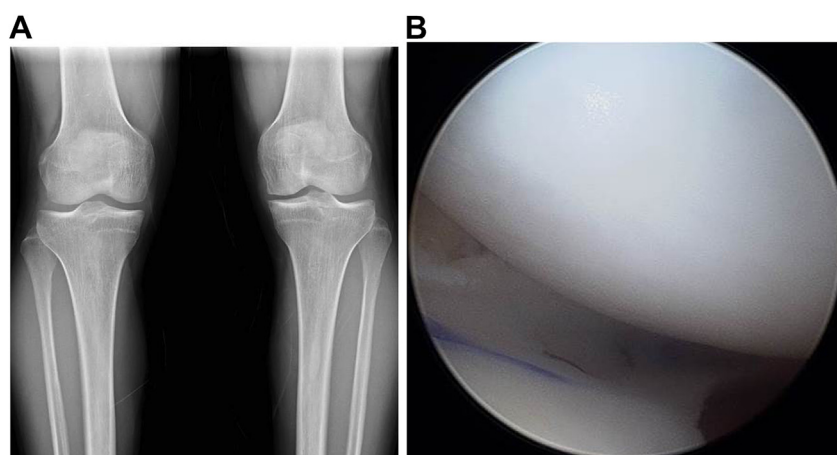


Fig. 2. Radiography and arthroscopic image of case 1 obtained 2 years after subtotal meniscectomy of the left knee. (a) Anteroposterior radiograph shows mild narrowing and marginal osteophyte in the medial compartment. (b) Medial meniscus allograft transplantation was performed using the bone plug technique.

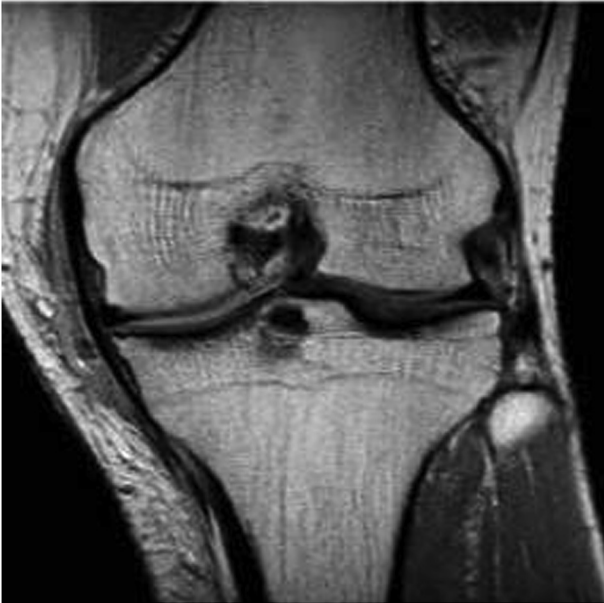

Fig. 3. Coronal T1-weighted MRI of the case 1 obtained through mid-portion of the medial femoral condyle 12 months after medial MAT. We considered subluxation of more than 3 mm to indicate extrusion.¹⁴ Meniscal subluxation was defined as the distance from the tibial plateau to the outer edge of the meniscus. Secure integration of the allograft with the joint capsule and good positioning in relation to the tibiofemoral joint were evident. No frank extrusion of the allograft out of the tibiofemoral joint was evident.

In March 2013, he suffered from pain in both knees, which was aggravated by climbing stairs and long-distance walking. No abnormality was observed on radiographs. MRI of both knees revealed worn-out medial femoral condyle and tibial condyle cartilage. A second-look arthroscopy on the left knee showed that the weight-bearing portion of the medial femoral condyle was not properly covered as a result of thinning due to a degenerative tear on the superior surface of the meniscus remaining after the meniscectomy, and cartilage wear of the femoral condyle was ongoing (Fig. 5a and b). The patient had difficulties in daily activities and as a professional soldier due to the persistent pain in the medial compartment of both knee joints. MAT was performed using the bone plug technique. Thirteen months after MAT on both knees, MRI of both knees showed sound peripheral healing of the joint capsule. The cartilage wear area on the medial femoral condyle side was well covered (Fig. 6a and b). At two years, clinical outcome was measured using a visual analog scale for pain (right: 2/left: 2), Lysholm score (right: 76/left: 78) and Tegner activity scale (level 5), with a normal range of movement.

Discussion

The origin of discoid meniscus is not well understood. Defective disappearance of the meniscal center during fetal development, with persistence of the fetal stage into adulthood has been suggested.⁸ Subsequent studies demonstrated that the embryonic meniscus never takes on a discoid shape.⁹ A recent histomorphological study demonstrated discontinuity and inhomogeneity of the

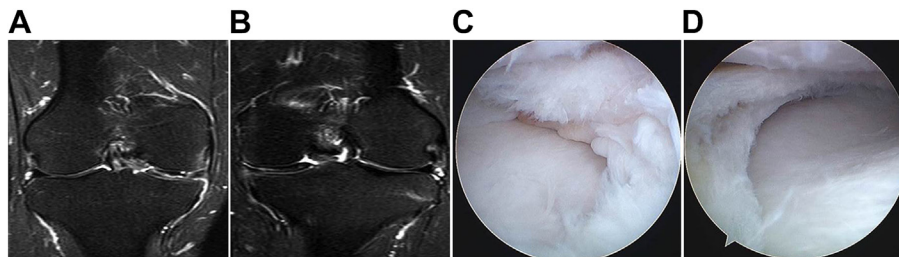


Fig. 4. MRI and arthroscopic images of a 21-year-old male (patient 2) who presented with pain and swelling in both knees. (a) Coronal T2-weighted image of the right knee showing a complex tear of the medial meniscus with the medial tibial plateau being completely covered. (b) Coronal T2-weighted image of the left knee showing complete discoid medial meniscus with a horizontal cleavage tear. (c) In probing of the peripheral side of the discoid medial meniscus of the right knee, a degenerative longitudinal tear running from the body portion to the posterior horn was observed, and the margin of the torn meniscus showed severe fatty degeneration. A subtotal meniscectomy was performed in the right knee. (d) Arthroscopic partial meniscectomy involving the torn meniscus was performed in the left knee. For the inner horizontal cleavage tear, the inferior surface was also resected.

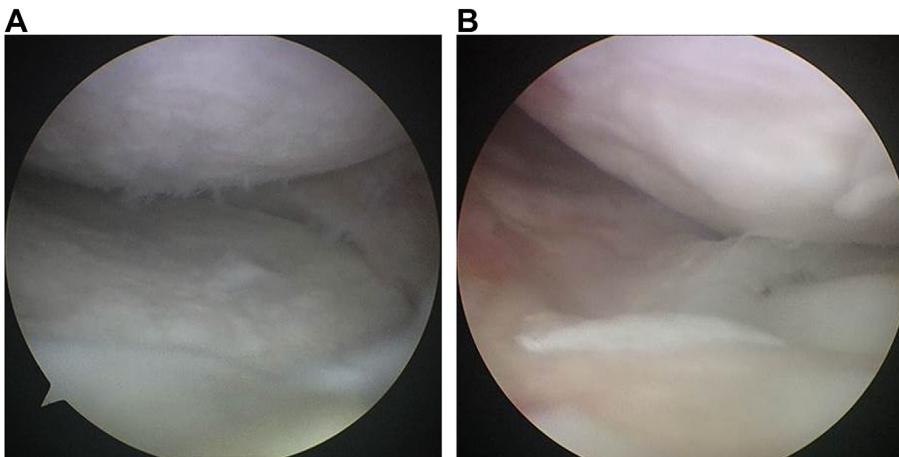


Fig. 5. Arthroscopic images of patient 2 obtained 3 years after meniscectomy of both knees. (a) Arthroscopic image of the right knee showing medial femoral condyle and tibial condyle cartilage undergoing wear. (b) Arthroscopic image of the left knee showing thinning due to degenerative tear on the superior surface of the meniscus remaining after the previous meniscectomy, with medial femoral condyle cartilage wear.

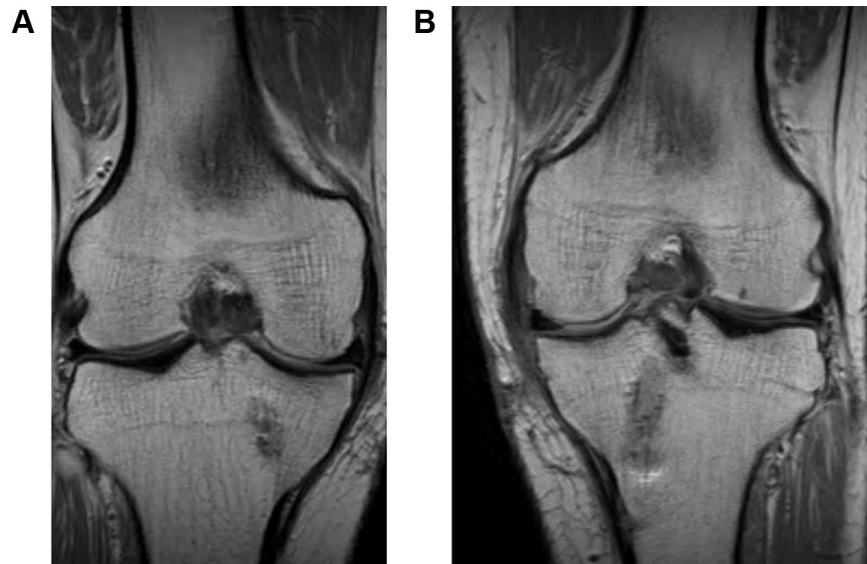

Fig. 6. MRI of patient 2 obtained 13 months after medial MAT of both knees. (a, b) Coronal T1-weighted image of both knees showing sound peripheral healing of the joint capsule. The cartilage wear area on the medial femoral condyle side was well covered.

circumferential collagen network in the discoid meniscus in comparison with the normal meniscus.¹⁰ So the discoid meniscus likely represents a structural lesion rather than a morphological variant and supports the argument that the discoid meniscus is susceptible to higher rates of tear and degeneration compared with meniscus of normal configuration. Discoid medial meniscus is generally diagnosed with tear and degeneration in young subjects with considerable functional and athletic demands.^{1,2} In both cases presented herein, bilateral discoid medial meniscus was diagnosed in highly active young males. Complex tear associated horizontal cleavage tear with meniscal cyst and degeneration were detected. Although treatment for discoid medial meniscus depends on the morphometrics and the tear pattern of the injured meniscus visualized and probed during arthroscopic surgery, most articles recommend partial meniscectomy and peripheral side repair as necessary.^{3,4} Total meniscectomy status increases the contact stress on articular cartilage, resulting in a painful joint because progression of the degeneration of articular cartilage may induce osteoarthritis, similar to a non-discoid meniscus.¹¹ Meniscectomy for discoid medial meniscus can yield promising short-term results and deteriorating long-term results, with secondary degeneration of cartilage in the medial compartment.²

Upon intermediate-term follow-up of the current cases, the knee of patient 1 revealed complex re-tearing of the remaining meniscus 4 years after partial meniscectomy. The knees of patient 2 revealed degenerative tearing of the remaining meniscus and cartilage wear of the femoral condyle 3 years after the meniscectomy. We believe that partial meniscectomy does not restore a normal discoid medial meniscus, unlike the non-discoid meniscus, because it remains thick and liable to snapping or residual pain. Furthermore, most reported symptomatic discoid medial menisci exhibited horizontal cleavage tears, attributable to the presence of myxoid degeneration in the intrameniscal substance. These degenerated remaining menisci after meniscectomy may be at high risk of complicated re-tearing of the free margin or secondary degeneration of cartilage in the medial compartment in young and active subjects.

MAT is an effective biologic reconstruction method for a meniscotomized knee that reduces symptoms in the affected compartment. Although complications including tear of the allograft, synovitis, effusion, or infection have been reported, when considering only isolated MAT, the acceptable complication rate is

3.6%.⁵ In a long-term study, radiological progression of arthritis was halted in 35% of patients after MAT, indicating a potential chondroprotective effect.¹² Some potential chondroprotective effect by which MAT reduces the progression of osteoarthritis have been suggested.¹³ The current cases had difficulties in daily activities and their occupations as young professional soldiers due to persistent pain in the medial compartment of knees after subtotal meniscectomy. MAT was performed using the bone plug technique in complicated bilateral discoid medial meniscus.

To our knowledge, follow-up of MAT of symptomatic bilateral discoid medial meniscus has not been reported previously. After over one year of follow-up after MAT, MRI showed sound peripheral healing of the joint capsule, and there was no frank extrusion of the allograft out of the tibiofemoral joint. After more than 2 years of follow-up after MAT, both patients remained free from pain. Lysholm and Tegner activity score was improved compared to before MAT. However, the patients' daily activities and sports abilities as Tegner activity scale level 5 were limited in comparison with healthy individuals of the same age group. We should bear in mind the possibility of future re-tearing of the allograft meniscus or progression of cartilage degeneration.

Partial meniscectomy is the principal treatment method for symptomatic discoid medial meniscus and can yield promising short-term results. However, because deteriorating long-term results with re-tearing of remaining meniscus or secondary degeneration of cartilage of the medial compartment can occur in highly active young patients, activity modification to prevent possible injury may be recommended. Meniscal allograft transplantation may be an alternative option in highly active young patients undergoing complicated discoid medial meniscus to diminish pain, improve knee function, and prevent or delay degeneration.

References

1. Elvey MH, Konan S, House CV, Patel RV. Horizontal cleavage tear of discoid medial meniscus diagnosed on MRI and treated with arthroscopic partial resection. *Knee Surg Sports Traumatol Arthrosc.* 2011;19:1860–1867.
2. Chen LX, Ao YF, Yu JK, et al. Clinical features and prognosis of discoid medial meniscus. *Knee Surg Sports Traumatol Arthrosc.* 2013;21:398–402.
3. Adachi N, Ochi M, Uchio Y, Kuriwaka M, Shinomiya R. Torn discoid lateral meniscus treated using partial central meniscectomy and suture of the peripheral tear. *Arthroscopy.* 2004;20:536–542.

4. Ahn JH, Lee SH, Yoo JC, Lee YS, Ha CH. Arthroscopic partial meniscectomy with repair of the peripheral tear for symptomatic discoid lateral meniscus in children: results of minimum 2 years of follow-up. *Arthroscopy*. 2008;24:888–898.
5. Rosso F, Bisicchia S, Bonasia DE, Amendola A. Meniscal allograft transplantation: a systematic review. *Am J Sports Med*. 2015;43:998–1007.
6. Shelton WR, Dukes AD. Meniscus replacement with bone anchors: a surgical technique. *Arthroscopy*. 1994;10:324–327.
7. Pollard ME, Kang Q, Berg EE. Radiographic sizing for meniscal transplantation. *Arthroscopy*. 1995;11:684–687.
8. Smillie IS. The congenital discoid meniscus. *J Bone Jt Surg Am*. 1948;30:671–682.
9. Clark CR, Ogden JA. Development of the menisci of the human knee joint. Morphological changes and their potential role in childhood meniscal injury. *J Bone Jt Surg Am*. 1983;65:538–547.
10. Papadopoulos A, Kirkos JM, Kapetanos GA. Histomorphologic study of discoid meniscus. *Arthroscopy*. 2009;25:262–268.
11. Raber DA, Friederich NF, Hefti F. Discoid lateral meniscus in children. Long-term follow-up after total meniscectomy. *J Bone Jt Surg Am*. 1998;80:1579–1586.
12. Verdonk PC, Verstraete KL, Almqvist KF, et al. Meniscal allograft transplantation: long-term clinical results with radiological and magnetic resonance imaging correlations. *Knee Surg Sports Traumatol Arthrosc*. 2006;14:694–706.
13. Lee BS, Bin SI, Kim JM. Articular cartilage degenerates after subtotal/total lateral meniscectomy but radiographic arthrosis progression is reduced after meniscal transplantation. *Am J Sport Med*. 2016;44:159–165.
14. Lee DH, Kim TH, Lee SH, Kim CW, Kim JM, Bin SI. Evaluation of meniscus allograft transplantation with serial magnetic resonance imaging during the first postoperative year: focus on graft extrusion. *Arthroscopy*. 2008;24:1115–1121.