

## A novel computer-based method for measuring the acetabular angle on hip radiographs



Seda Sahin <sup>a</sup>, Emin Akata <sup>a</sup>, Orcun Sahin <sup>b,\*</sup>, Cengiz Tuncay <sup>b</sup>, Hüseyin Özkan <sup>c</sup>

<sup>a</sup> Department of Electrical and Electronics Engineering, Baskent University, Ankara, Turkey

<sup>b</sup> Department of Orthopaedic and Traumatology, Baskent University Hospital, Ankara, Turkey

<sup>c</sup> Department of Orthopaedic and Traumatology, Gulhane Military Medical Academy Hospital, Ankara, Turkey

### ARTICLE INFO

#### Article history:

Received 5 January 2016

Received in revised form

13 July 2016

Accepted 15 September 2016

Available online 12 January 2017

#### Keywords:

Acetabular angle

Computer-based measurement

Hip radiograph

Obturator foramen

Pelvic angle

Pelvic X-ray

### ABSTRACT

**Objective:** The aim of this study was to propose a new computer based method for measuring acetabular angles on hip radiographs and to assess its practicality, sensitivity and reliability for acetabular angle measurement.

**Methods:** A total of 314 acetabulum were assessed on 157 pelvic X-ray images. Acetabular angles were measured with both the conventional method (Method 1) and our proposed method (Method 2). All the Acetabular Index (AI) angle, Acetabular Angle (AA) and Acetabular Center (ACM) angle were measured with both methods.

**Results:** The mean AI angle for Method 1 is  $11.02^\circ \pm 2.7^\circ$  and the mean AI angle for Method 2 is  $10.08^\circ \pm 1.88^\circ$ , the mean AA angle for Method 1 is  $39.5^\circ \pm 5.3^\circ$  and the mean AA angle for Method 2 is  $39.36^\circ \pm 4.68^\circ$ , the mean ACM angle for Method 1 is  $50.5^\circ \pm 6.01^\circ$  and the mean ACM angle for Method 2 is  $55.42^\circ \pm 12.43^\circ$ .

**Conclusion:** Our novel automated method appear to be reliable and practical for acetabular angle measurement on hip radiographs.

**Level of Evidence:** Level III, Diagnostic study

© 2017 Turkish Association of Orthopaedics and Traumatology. Publishing services by Elsevier B.V. This is an open access article under the CC BY-NC-ND license (<http://creativecommons.org/licenses/by-nc-nd/4.0/>).

Anteroposterior (AP) pelvic X-ray imaging is one of the most commonly used radiographic projections of the pelvis. Assessment of the acetabular morphology and the femoral head-acetabulum congruency with angular measurements is one of the basic steps of AP pelvis radiographical analysis.<sup>1,2</sup> For this reason, an easy, reliable and accurate measurement of the acetabular angle is very important.<sup>3</sup> In the literature, various techniques have been proposed for acetabular angle measurements, including the acetabular index (AI), defined by Hilgenreiner and Tönnis<sup>4</sup>; acetabular angle (AA), defined by Sharp<sup>5</sup>; and acetabular center–margin (ACM) angle, defined by Idelberger and Frank.<sup>6</sup> The AI and AA angles provide information about the slope of the acetabulum while the ACM angle measures its depth. These angles are the most

preferable ‘conventional manual angle measurement methods’. Nevertheless, there is still an ongoing debate in the literature about the gold standard measurement method, since the manual measurement of the acetabular angle is very dependent on the experience of the observer and the quality of the AP radiograph.<sup>7</sup> To overcome these controversies, methods about the computer-assisted extraction of new anatomical landmarks and calculation of angles automatically on hip radiographs have been recently developed.<sup>8–14</sup>

In this paper, we aimed to describe new anatomical landmarks and reference lines in regards to establishing a fully automated acetabular angle measurement method which is based on the obturator foramen.

### Patients and methods

Between January 2014 and December 2014 and between June 2011 and May 2012, all patients who were admitted to Orthopedics Department in outpatient clinics in two different hospitals (one university hospital, one military hospital), and who were scheduled

\* Corresponding author. Baskent University Hospital, Dep. of Orthopaedics and Traumatology, Maresal Fevzi Cakmak Cad. 10. sok No:45, 06490, Bahcelievler, Ankara, Turkey. Fax: +90 312 223 73 33.

E-mail address: [drorcunsaahin@gmail.com](mailto:drorcunsaahin@gmail.com) (O. Sahin).

Peer review under responsibility of Turkish Association of Orthopaedics and Traumatology.

to undergo pelvic X-ray evaluation, were considered for this study. This study was approved by the Institutional Review Board of Başkent University (November 28, 2013) and ethical approval was received from Gülhane Military Medical Academy Hospital Ethics Committee (May 25, 2011). In order to prevent any bias and to acquire a homogenous study population, all X-rays were taken under a standard procedure.

As an inclusion criterion, only 'mature pelvic X-rays' without obvious osteophyte formation, bone defects or other pathological changes on the acetabular rim were accepted. Patients who had a previous pelvic or lumbosacral surgery, previous fracture history regarding the acetabulum, or patients with coxarthrosis, severe bone deformities and metabolic bone disorders, radiographs of suboptimal quality, and an excessive pelvic rotation as assessed by an obturator foramen index beyond the range of 0.6–1.8<sup>4</sup> were excluded from the analyses. Eventually, a total of 157 pelvic X-rays (314 hips) were found eligible. The study group consisted of 123 male and 43 female patients with a mean age of  $56.7 \pm 13.3$  years.

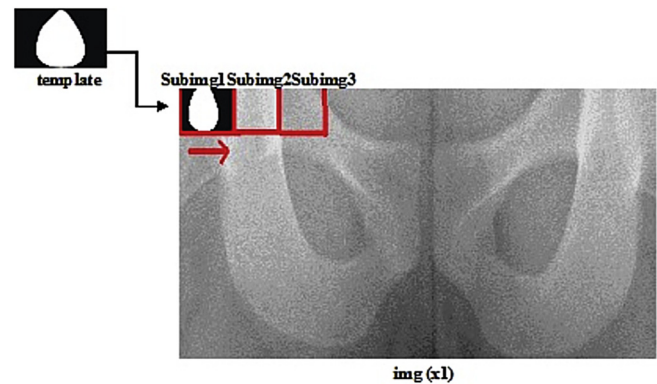
All X-rays were digitally recorded in the Orthopedics Department and the PACS v.2.0 (picture archiving and communications systems) software was used to store the DICOM (Digital Imaging and Communications in Medicine) images.

All conventional manual measurements (Method 1) were done with two experienced observers after printing the high-quality pelvic X-ray images. In order to perform the standardized measurements as precisely as possible, a detailed common understanding of important pelvic landmarks of all the measurements was ensured prior to the analyses.

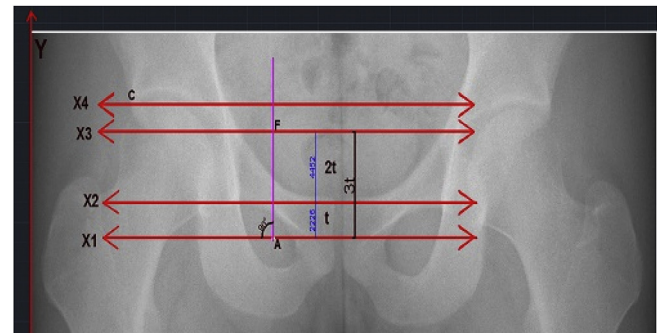
Three previously mentioned acetabular measurement methods were used for the conventional radiographic evaluation:

1. Acetabular index (AI) defined by Hilgenreiner and Tönns. AI is the angle between the horizontal teardrop line and a line drawn through the medial point of the sourcil and the lateral acetabular rim.
2. Acetabular angle (AA) defined by Sharp. AA is the angle between the horizontal teardrop line and a line through the inferior teardrop point and the lateral rim of the acetabulum.
3. Acetabular center–margin (ACM) angle defined by Idelberger and Frank. The ACM is defined as the angle between the MC and CA lines constructed on the acetabulum. (A: the upper point of acetabulum, B: the lower point of the acetabulum, C: the intersection point of the acetabulum with the orthogonal line drawn from the center of the AB line, MC: the line which was passed through the center of the AB line, CA: the line that connects the A and C points.)

Our proposed method (Method 2) is a novel, geometric method which uses the AutoCAD 2013 (Autodesk Inc., San Rafael, CA, USA) and MATLAB 7.13.0 (The MathWorks Inc., Natick, MA, USA) softwares. First, a reference image was determined by clinicians as a gold standard image and it was used to present the proposed novel geometric angle measurement method drawings. The image was transferred to AutoCAD and was opened on the user interface. Then, a hand drawn template was designed on this interface based on the reference image. After that, the fully automated angle measurement algorithm framework was developed on MATLAB. 157 images were executed for each run of this algorithm and angle measurement results were produced as an output. The template was operated on a sample image (x1) row by row (Fig. 1) to find the best fitting sub-image as the obturator foramen, by using some image processing techniques whose descriptions are beyond the scope of this paper. After the obturator foramen was detected, its center of mass was determined as the major reference point for all subsequent measurements. The measurements of acetabular angles



**Fig. 1.** Identifying the starting reference point (center of mass of the obturator foramen). Note that, first, a hand-drawn template is designed in AutoCAD. Then, it is operated on the hip radiograph (x1) to detect similarities between the sub-images and this is used to decide the most similar sub-image to the template image as the obturator foramen. Then, the center of mass of the obturator foramen is identified.



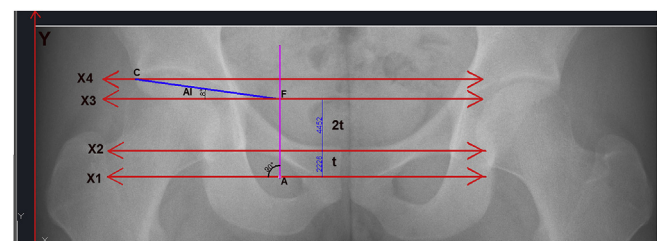
**Fig. 2.** Reference lines are drawn automatically after detection of the center of mass of the obturator foramen. **X1 line:** The line parallel to the X-axis and passes through the center of mass of the obturator foramen (Point A) and intersects with the Y-axis. **X2 line:** The reference line parallel to the X1-axis and passes through the superior margin of the obturator foramen and intersects with the Y-axis. The distance between these two lines are referred as "t" distance. **X3 line:** The line parallel to the X2-axis and passes through 3t above the center of mass of the obturator foramen and intersects with the Y-axis. **X4 line:** The reference line which is parallel to the X3-axis and passes through the lateral margin of the acetabular roof (Point C) and intersects with the Y-axis. After establishing these reference lines, the angular measurements are performed by the computerized method.

were based on the four reference lines which were drawn automatically, as the second step of the proposed method (Fig. 2).

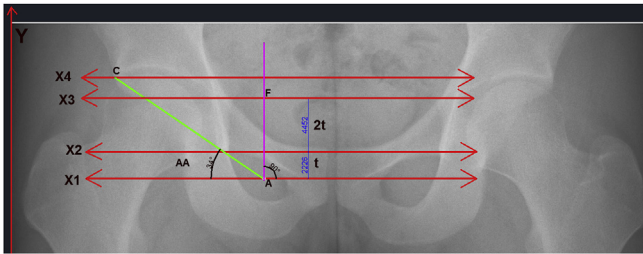
The angle formed between the X3 line and the line drawn from point F to point C was accepted as AI (Fig. 3).

The angle formed between the X1 line and the line drawn from point A to point C was accepted as AA (Fig. 4).

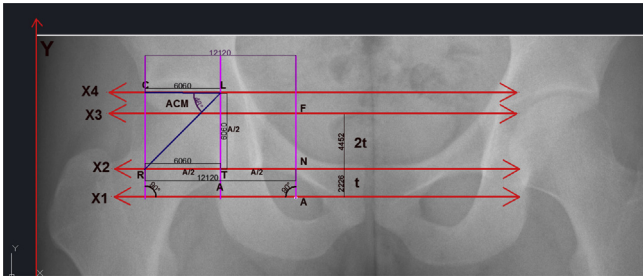
The angle formed between the LR line and the CL line was accepted as ACM angle. The method of measurement is summarized in Fig. 5.



**Fig. 3.** Geometrical-based measurement method for the acetabular index (AI). The AI is the angle formed between the CF and X3 lines.



**Fig. 4.** Geometrical-based measurement method for the acetabular angle (AA). The AA is the angle formed between the CA and X1 lines.



**Fig. 5.** Geometrical-based measurement method for the acetabular center–margin (ACM) angle. The ACM angle is formed between the LR and the CL lines. **A distance:** The distance which is between Point R and Point N. **T:** The reference point located on the middle of the A distance. **L:** The reference point located on A/2 unit above Point T. **R:** The reference point located on the line between Point L and the point of intersection of the X2 line.

All measurements with the conventional (Method 1) and proposed (Method 2) methods were recorded in a database and their mean values and standard deviations were calculated. Angular measurements were also analyzed to see if there are any differences based on gender. Then, all the data derived from the conventional and proposed methods were statistically compared. Compliance with the normal distribution of continuous variables was checked with the Shapiro–Wilk test. Homogeneity of groups' variances was checked by Levene's test. After the distribution of data and homogeneity of variances in these data were found normal, a paired sample t-test which was based on the comparative results for the two different angle measurement methods on same images was used. The SPSS v.17.0 (SPSS Inc., Chicago, IL, USA) and MedCalc 13.1.0.0 (MedCalc Software, Ostend, Belgium) statistical package programs were used for the analysis of the data set. The level of statistical significance was set at  $p < 0.05$ .

## Results

A total of 157 pelvic X-rays (314 hips) were analyzed. The homogeneity of age and gender variances within the study group was normal.

For Method 1, the mean AI values for the hips in males and females were  $10.85^\circ \pm 2.44^\circ$  and  $11.12^\circ \pm 3.01^\circ$ , respectively, and there was no statistically significant difference ( $p = 0.52$ ). For Method 2, the mean AI values for the hips in males and females were  $10.03^\circ \pm 1.96^\circ$  and  $10.14^\circ \pm 1.80^\circ$ . Again, no statistically significant difference was detected between males and females in comparison to the proposed method ( $p = 0.66$ ).

Using Method 1 and Method 2, the mean AI values were  $11.02^\circ \pm 2.7^\circ$  and  $10.08^\circ \pm 1.88^\circ$ , respectively. There was a statistically significant difference between Method 1 and Method 2 ( $p = 0.01$ ). The mean AI values for the two methods regarding each side, gender, and statistical p values are summarized in Tables 1–3.

**Table 1**

The mean and standard deviation values of the acetabular angles for Method 1 and 2 and their statistical p values.

| Angles | Method 1 (Mean $\pm$ SD)     | Method 2 (Mean $\pm$ SD)      | p    |
|--------|------------------------------|-------------------------------|------|
| AI     | $11.02^\circ \pm 2.70^\circ$ | $10.08^\circ \pm 1.88^\circ$  | 0.01 |
| AA     | $39.50^\circ \pm 5.30^\circ$ | $39.36^\circ \pm 4.68^\circ$  | 0.37 |
| ACM    | $50.50^\circ \pm 6.01^\circ$ | $55.42^\circ \pm 12.43^\circ$ | 0.01 |

AA: acetabular angle, ACM angle: acetabular center–margin angle, AI: acetabular index, SD: standard deviation.

Using Method 1, the mean AA values for the hips in males and females were  $38.55^\circ \pm 5.28^\circ$  and  $39.55^\circ \pm 5.32^\circ$ , respectively. There was no statistically significant difference between male and female patients in comparison to the conventional method ( $p = 0.23$ ). For Method 2, the mean AA values for male and female patients were  $39.04^\circ \pm 4.53^\circ$  and  $39.68^\circ \pm 4.83^\circ$ , respectively. Again no statistically significant difference was found between male and female patients in comparison to the proposed method ( $p = 0.39$ ).

Using Method 1 and Method 2, mean AA measurements were  $39.50^\circ \pm 5.30^\circ$  and  $39.36^\circ \pm 4.68^\circ$ , respectively. No statistically significant difference was detected between Method 1 and Method 2 ( $p = 0.37$ ). The mean AA values for the two methods regarding each side, gender and statistical p values are summarized in Tables 1–3.

Using Method 1, the mean ACM values in males and females were  $50.26^\circ \pm 5.20^\circ$  and  $50.74^\circ \pm 6.83^\circ$ , respectively. There was no statistically significant difference between males and females in comparison to the conventional method ( $p = 0.64$ ). Using Method 2, the mean ACM angle values in male and female hips were  $54.50^\circ \pm 11.24^\circ$  and  $56.35^\circ \pm 13.63^\circ$ , respectively. There was also no statistically significant difference between male and female patients in comparison to the proposed method ( $p = 0.38$ ).

Using Method 1 and Method 2, the mean ACM angle values were noted as  $50.50^\circ \pm 6.01^\circ$  and  $55.42^\circ \pm 12.43^\circ$ , respectively. There was a significant difference between Method 1 and Method 2 ( $p < 0.01$ ). The mean ACM values for the two methods regarding each side, gender and statistical p values are summarized in Tables 1–3.

## Discussion

Reliable orthopedic measurements have significant importance in correctly detecting and diagnosing different types of orthopedic diseases. The automated angle measurement system can utilize clinicians' studies and offers an objective evaluation for these measurements. In this study, the main purpose was to develop a new computer-based angle measurement system whose measurements on an optimal level approximate to the clinician's manual measurements.

This study is one of the first multidisciplinary studies in the literature which gives us a new perspective for some of the most commonly used acetabular angle measurement methods. In this study, a collaboration of orthopedic medicine and computer sciences has been achieved to define a novel acetabular angle measurement method based on a fully automated computer-based technique.

In the literature, it is very well-known that the acetabular angle measurements are very crucial for the detection of some major hip pathologies, including hip dysplasia.<sup>1,2,7,9,11,15,16</sup> Nevertheless, the gold standard method for the measurement of the acetabulum, the femoral head and its relationship with the pelvis on plain radiographs is still a matter of discussion.<sup>17,18</sup> We believe that, to have precise measurements of the acetabular angles, the method should be easy-to-use, reliable and consistent. A computer-based technique can provide these features with the advantage of prevention of any observer bias. Although, the computer-based measurements

**Table 2**

The mean and standard deviation values of the acetabular angles for the right and left hips and their statistical p values.

| Angles | Method 1 (Mean ± SD) |               |        | Method 2 (Mean ± SD) |               |       |
|--------|----------------------|---------------|--------|----------------------|---------------|-------|
|        | Right                | Left          | p      | Right                | Left          | p     |
| AI     | 11.06°±6.3°          | 10.91°±6.07°  | 0.318  | 10.25°±2.10°         | 9.92°±1.74°   | 0.492 |
| AA     | 38.66°±4.59°         | 39.44°±4.41°  | 0.510  | 39.60°±4.70°         | 39.12°±4.50°  | 0.096 |
| ACM    | 52.35°±12°           | 48.65°±12.79° | <0.001 | 56.43°±12.06°        | 54.42°±11.52° | 0.110 |

AA: acetabular angle, ACM angle: acetabular center–margin angle, AI: acetabular index, SD: standard deviation.

**Table 3**

The mean and standard deviation values of the acetabular angles for male and female patients and their statistical p values.

| Angles | Method 1 (Mean ± SD) |              |      | Method 2 (Mean ± SD) |               |      |
|--------|----------------------|--------------|------|----------------------|---------------|------|
|        | Male                 | Female       | p    | Male                 | Female        | p    |
| AI     | 10.85°±2.44°         | 11.12°±3.01° | 0.52 | 10.03°±1.96°         | 10.14°±1.80°  | 0.66 |
| AA     | 38.55°±5.28°         | 39.55°±5.32° | 0.23 | 39.04°±4.53°         | 39.68°±4.83°  | 0.39 |
| ACM    | 50.26°±5.2°          | 50.74°±6.83° | 0.64 | 54.5°±11.24°         | 56.35°±13.63° | 0.38 |

AA: acetabular angle, ACM angle: acetabular center–margin angle, AI: acetabular index, SD: standard deviation.

were previously published in the literature in orthopedics research field, including computer-assisted surgeries and radiographic measurements,<sup>19,20</sup> there is no study that solely analyzes the acetabular angle measurements on pelvic X-ray images to diagnose pelvic diseases for different age groups, via a fully automated and specifically designed computer-based approach. Thus, for this study, we have developed a specific computer-based technique, in order to measure the most commonly used acetabular angles in an automatic manner, and compared our new method to the classic manual measurement techniques. The detailed description of the computing techniques and algorithms are left beyond the scope of this paper.

There are several angular measurement methods in the literature, which define different aspects of hip dysplasia, including acetabular depth, acetabular inclination, femoral head–acetabular congruency, and femoral anteversion.<sup>1,2,7,11,12,16</sup> These angles are required for the identification of radiographic quantitative factors predictive of long-term outcome for hip dysplasia, since a poor anatomic result is often detectable long before clinical symptoms appear.<sup>1</sup> Nevertheless, most of these manual angular measurements are highly observer-dependent, need experience, technically demanding and have low interobserver reliability. In order to overcome these controversies, many reliability and reproducibility studies have been reported in the literature.<sup>10–13,21,22</sup> In a study by Nelitz et al, 100 hip radiographs of adult patients with hip dysplasia were analyzed for the reliability of the most common radiographic measurement methods and the authors concluded that the AI and the ACM angle have low inter- and intraobserver reliability.<sup>23</sup> In another study by Kay et al, 24 anteroposterior pelvis radiographs were evaluated for manual AI measurements by five observers, including three senior orthopedic residents and two attending pediatric orthopedic surgeons.<sup>24</sup> As a result, it was concluded that manual AI measurements had large inter- and intraobserver variability.

In the last decade, with the advancement in computer science and technology, there is an increasing demand for the development of digitalized and/or computer-based measurement methods. At the beginning, the technical development in digital photo technology and establishment of PACS have provided better ways for dealing with these issues. Although this rapid progress of digital imaging modalities have led to more systematic, automated measurements in radiographic studies, the development of computer-based techniques, which provides a fully automated calculation of acetabular angles, is still lagging behind.<sup>25</sup> In a study by Pedersen

et al, the results of a digitizing program which determines 12 anatomic locations on AP pelvic radiographs were analyzed, and the authors concluded that the method demonstrated very good reliability coefficients.<sup>13</sup> The limitation with Pedersen's study is that, the method does not have a fully automated manner, i.e. after detection of the landmarks, the measurements are done by observers, not by the program itself. In another study by Engesaeter et al,<sup>11</sup> manual versus digital measurement techniques were compared for hip dysplasia in skeletal maturity. Pelvic radiographs from 95 participants were included and three observers measured the radiographs using both a digital measurement program and manually. Thus, it was concluded that, regardless of the measurement technique, there was a large variation between observers. The major drawback for Engesaeter's study is also the digital measurement technique which is mainly observer-dependent. We believe that, although these previously defined different digital measurement techniques enable us to determine the anatomic landmarks and draw the angular lines definitely, the final angle measurements are done by the observers which may lead to variability. To overcome this issue, a digital program should measure the angles in a fully automated manner to prevent any observer bias, and to have a more standardized and reliable angle measurement.

In this study, a fully automated computer-based technique was designed for the calculation of the acetabular angles on digital AP pelvic radiographs. The approach accepts the obturator foramen as the major landmark for the calculations. For this reason, the pelvic X-ray used for the measurements should have no pelvic rotation, and the obturator foramen must be clearly visible in order to have the most accurate results. The major drawback of this approach is the distorted shape of the obturator foramen. Pelvic X-rays from patients who had previous fractures of the ischium or pubis, leading to distorted shape of the obturator foramen, are not suitable for this approach. In our study, we compared our proposed method with the conventional manual measurement. We believe that, due to its fully automatic characteristics, our new approach has reliable, consistent and close results with the classic manual measurement method. The clinical importance of this automated radiographic evaluation is to understand the anatomy and disease patterns seen in the pelvis, which improve the clinician's ability to make the correct diagnosis.

Some of the limitations of our study must be acknowledged. First, a study population with a larger number of X-rays must be analyzed in order to have more accurate results. Second, although

the angles obtained by the proposed method had comparable results with those in the literature, reliability tests should be performed in computer sciences. And finally, we studied only three acetabular angles; more and various angular measurements must be also evaluated in order to broaden the application of our approach in orthopedic medicine.

In conclusion, this new approach enables us to calculate the acetabular angles without any need for manual measurements. Our method is easy-to-use, reliable and efficient. We believe that, with the use of this proposed method, physicians can give objective results which provide a consistent prognostic factor for patients who had acetabular dysplasia and other orthopedic diseases. Additionally, the angle measurement tables are constructed to determine the angle intervals for normal cases in this study; thus, future studies featuring different acetabular angles with larger study populations for different bone diseases are required.

### Conflict of interests

The authors declare that they have no conflict of interest related to the study.

### References

- Campbell SE. Radiography of the hip: lines, signs, and patterns of disease. *Semin Roentgenol.* 2005;40:290–319.
- Swagerty Jr DL, Hellinger D. Radiographic assessment of osteoarthritis. *Am Fam Physician.* 2001;64:279–286.
- Goker B, Gonen E, Demirag MD, Block JA. Quantification of the radiographic joint space width of the ankle. *Clin Orthop Relat Res.* 2009;467:2083–2089.
- Tonnis D. Normal values of the hip joint for the evaluation of X-rays in children and adults. *Clin Orthop Relat Res.* 1976;39–47.
- Sharp I. Acetabular dysplasia. The acetabular angle. *J Bone Jt Surg [Br].* 1961;43:268–272.
- Idelberger K, Frank A. Über eine neue Methode zur Bestimmung des Pfannendachwinkels beim Jugendlichen und Erwachsenen (in German). *Z Orthop.* 1952;82:571–577.
- Lee YK, Chung CY, Koo KH, Lee KM, Kwon DG, Park MS. Measuring acetabular dysplasia in plain radiographs. *Arch Orthop Trauma Surg.* 2011;131:1219–1226.
- Al-Bashir AK, Al-Abed M, Abu Sharkh FM, Kordeya MN, Rousan FM. Algorithm for automatic angles measurement and screening for Developmental Dysplasia of the Hip (DDH). In: *Conference Proceedings: ... Annual International Conference of the IEEE Engineering in Medicine and Biology Society. IEEE Engineering in Medicine and Biology Society. Annual Conference 2015.* 2015:6386–6389.
- Clohisy JC, Carlisle JC, Beaulé PE, et al. A systematic approach to the plain radiographic evaluation of the young adult hip. *Journal Bone Jt Surg. American Volume.* 2008;90(4):47–66.
- Conrozier T, Brandt K, Piperno M, Mathieu P, Merle-Vincent F, Vignon E. Reproducibility and sensitivity to change of a new method of computer measurement of joint space width in hip osteoarthritis. Performance of three radiographic views obtained at a 3-year interval. *Osteoarthr Cartilage/OARS Osteoarthr Res Soc.* 2009;17:864–870.
- Engesaeter IO, Laborie LB, Lehmann TG, et al. Radiological findings for hip dysplasia at skeletal maturity. Validation of digital and manual measurement techniques. *Skelet Radiol.* 2012;41:775–785.
- Nagao Y, Aoki H, Ishii SJ, Masuda T, Beppu M. Radiographic method to measure the inclination angle of the acetabulum. *J Orthop Sci: Official Journal of the Japanese Orthopaedic Association.* 2008;13:62–71.
- Pedersen DR, Lamb CA, Dolan LA, Ralston HM, Weinstein SL, Morcuende JA. Radiographic measurements in developmental dysplasia of the hip: reliability and validity of a digitizing program. *J Pediatr Orthop.* 2004;24:156–160.
- van der List JP, Witbreuk MM, Buizer AI, van der Sluijs JA. The prognostic value of the head-shaft angle on hip displacement in children with cerebral palsy. *J Children's Orthop.* 2015;9:129–135.
- Agus H, Bicimoglu A, Omeroglu H, Tumer Y. How should the acetabular angle of Sharp be measured on a pelvic radiograph? *J Pediatr Orthop.* 2002;22:228–231.
- Ozcelik A, Omeroglu H, Inan U, Ozyurt B, Seber S. Normal values of several acetabular angles on hip radiographs obtained from individuals living in the Eskisehir region. *Acta Orthop Traumatol Turc.* 2002;36:100–105.
- Boniforti FG, Fujii G, Angliss RD, Benson MK. The reliability of measurements of pelvic radiographs in infants. *J Bone Jt Surg. British Volume.* 1997;79:570–575.
- Mast NH, Impellizzeri F, Keller S, Leunig M. Reliability and agreement of measures used in radiographic evaluation of the adult hip. *Clin Orthop Relat Res.* 2011;469:188–199.
- Radermacher K, Porthoine F, Anton M, et al. Computer assisted orthopaedic surgery with image based individual templates. *Clin Orthop Relat Res.* 1998;28–38.
- Tanure MC, Pinheiro AP, Oliveira AS. Reliability assessment of Cobb angle measurements using manual and digital methods. *Spine J Official J North Am Spine Soc.* 2010;10:769–774.
- Bouttler R, Morvan J, Mazieres B, et al. Reproducibility of radiographic hip measurements in adults. *Jt Bone Spine Rev Rhum.* 2013;80:52–56.
- Terjesen T, Gunderson RB. Reliability of radiographic parameters in adults with hip dysplasia. *Skelet Radiol.* 2012;41:811–816.
- Nelitz M, Guenther KP, Gunkel S, Puhl W. Reliability of radiological measurements in the assessment of hip dysplasia in adults. *Br J Radiol.* 1999;72:331–334.
- Kay RM, Watts HG, Dorey FJ. Variability in the assessment of acetabular index. *J Pediatr Orthop.* 1997;17:170–173.
- Arenson RL, Andriole KP, Avrin DE, Gould RG. Computers in imaging and health care: now and in the future. *J Digit Imaging.* 2000;13:145–156.